

Case index

MyoStrain® Heart Health Assessment

1 | Normal patient

2 | Hypertensive Heart Disease with Undiagnosed LBBB Post COVID-19

3 | Myocarditis Missed with Echocardiography

4 | Peri-Myocarditis with Improving Myocardial Function

5 | Dilated Cardiomyopathy Treated with Immunosuppressive & Entresto

6 | Hypertensive Heart Disease with Moderately Reduced Ejection Fraction

7 | Right Heart Dysfunction in Severe Pulmonary Hypertension

8 | Apical Hypertrophic Cardiomyopathy

9 | Hypertrophic Obstructive Cardiomyopathy

10 | Hypertrophic Cardiomyopathy in Asymptomatic Athlete

11 | MyoHealth® Monitors Amyloidosis Management

12 | Mitral Valve Disease (pre Mitra-Clip) with Preserved LVEF

13 | Tachymyopathy with Substantial Dyssynchrony

14 | Subclinical Cardiotoxicity with Reduced Stroke Volume Index

15 | Subclinical Cardiotoxicity with Reduced Stroke Volume Index

MyoStress® Heart Health Assessment

16 | Prior Transmural Posterior RCA Infarct without Ischemia

17 | Ischemic Coronary Artery Disease with 90% LAD & 90% RCA Stenoses

18 | Improvement in Function Post-PCI Despite Ischemia in Residual 90% Diagonal Stenosis

19 | 4-MyoStress Indicating Ischemic CAD Consistent with Catheterization



1 | Normal patient

Patient history

- 25-year Female Non-Smoker
- Body Mass Index – 20 kg/m²
- NYHA I
- Sinus Tachycardia
- Chronic Sinus Infections
- NO Myocarditis

Clinical findings

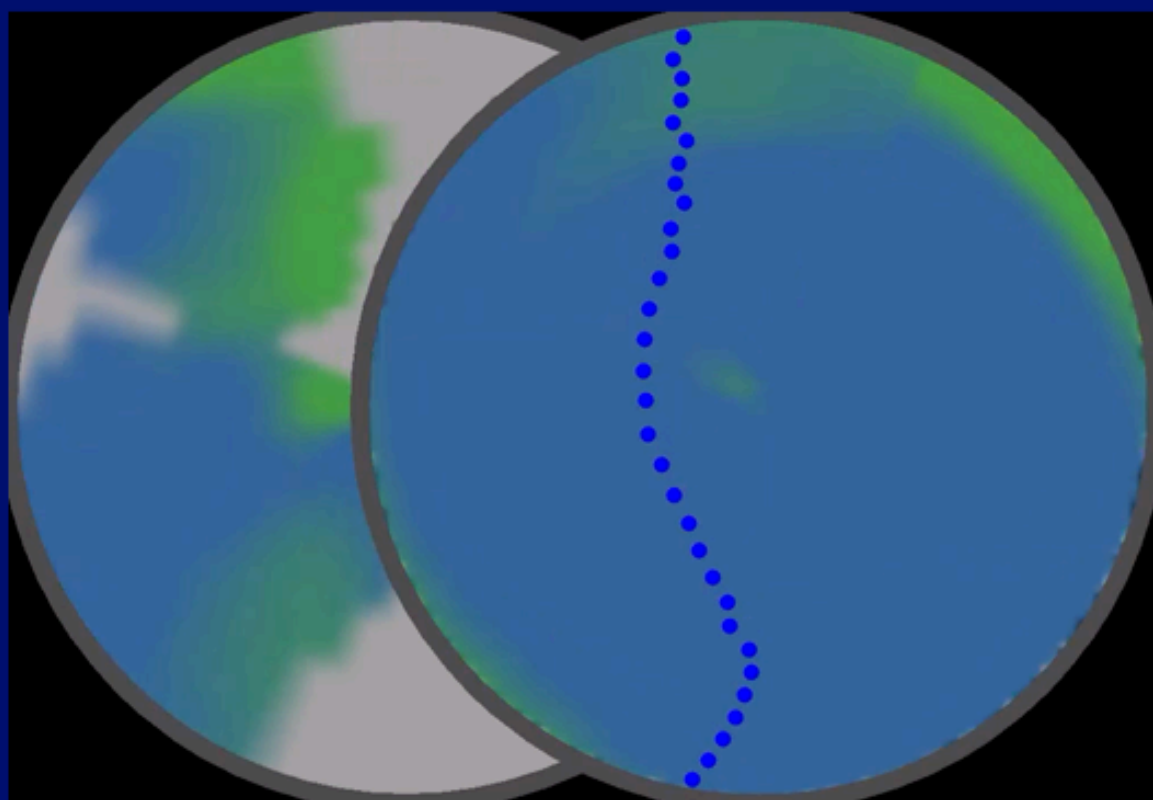
- LVEF – 57%, LVEDVI – 85 ml/m², LVESVI – 36 ml/m²
- LVSVI – 49 ml/m²
- Septal WT – 7 mm, Lateral WT – 4 mm,
- MAPSE – 15 mm, Mass Index – 42 g/m²
- RVEF – 55%, RVSVI – 43 ml/m², TAPSE – 25 mm
- Ascending Aorta – 20 mm, LA Diameter – 29 mm
- Pulmonary Trunk Diameter – 18 mm, NO LGE



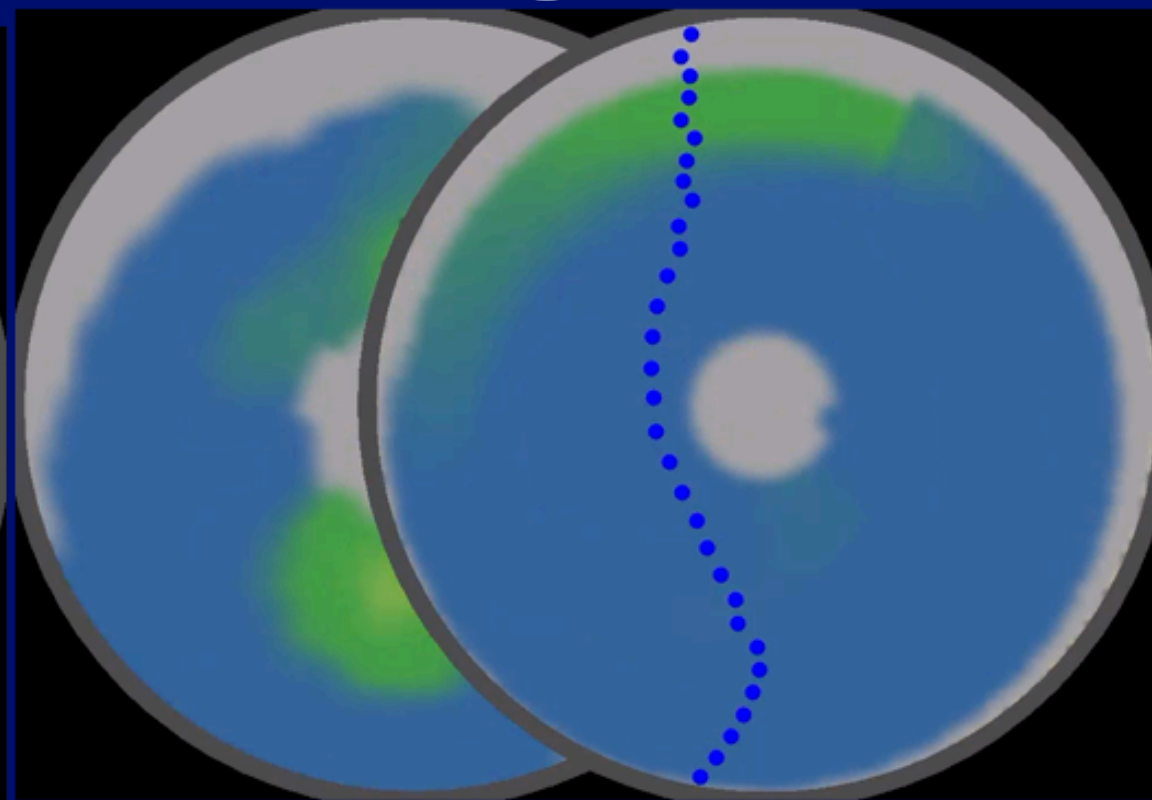
1 | Normal patient

MYOSTRAIN IMAGING


Circumferential



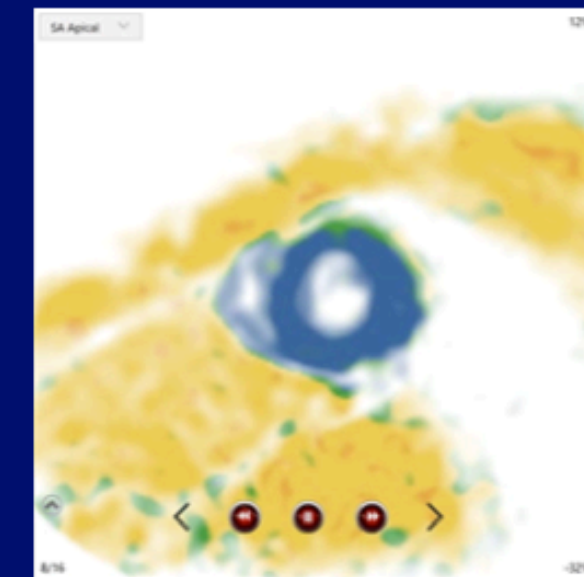
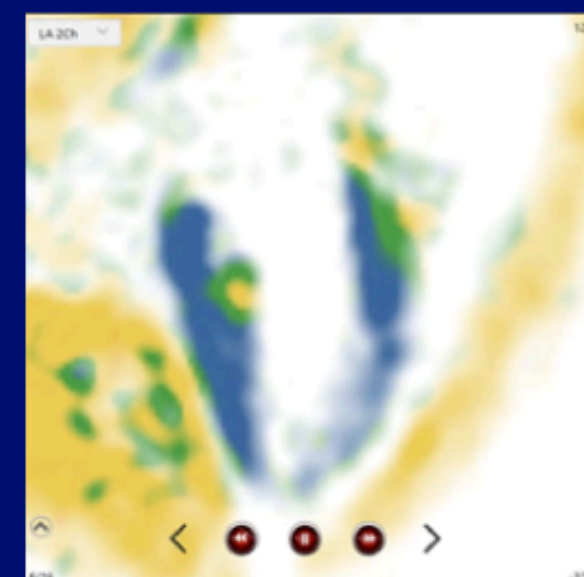
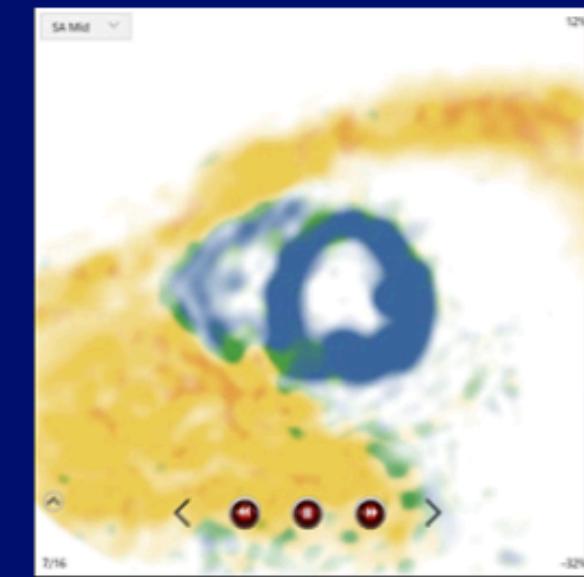

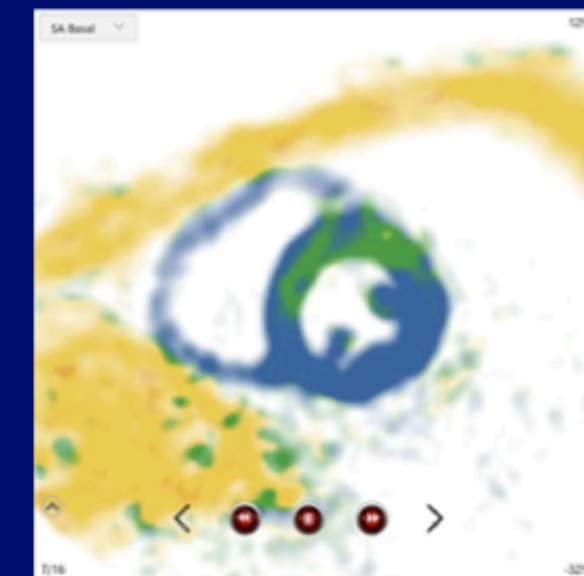
Longitudinal



Circumferential



Longitudinal



1 | Normal patient

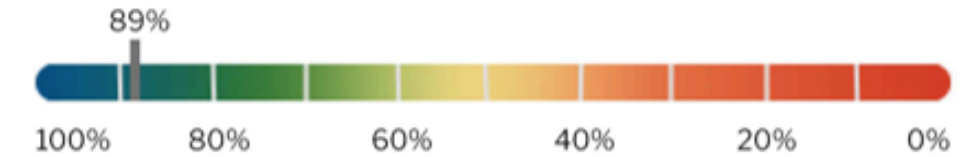
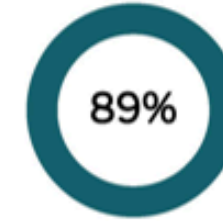LV Dysfunctional Segments ^[1]

(37/37 Segments Analyzed)

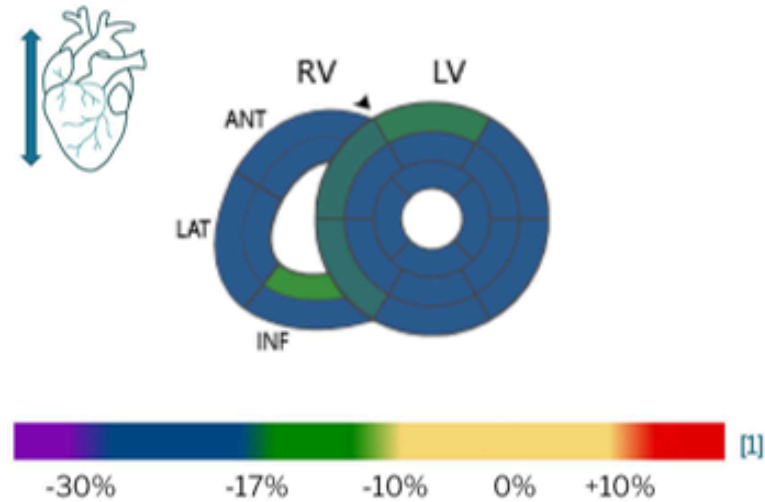
Number of Segments >-10% 0

Number of Segments >-17% 4

LV MyoHealth® (% Normal Segments ≤ -17%) ^[2]

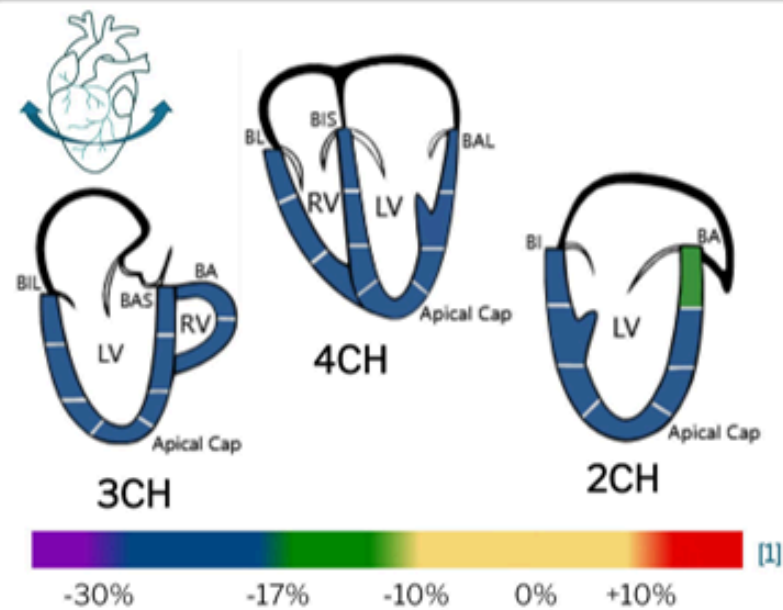


Longitudinal MyoStrain® Measurements



	Basal (HR: 72)	Mid (HR: 72)	Apical (HR: 72)			
LV	Anterior	-15.8 %	Anterior	-20.2 %	Anterior	-21.1 %
	Anteroseptal	-16.7 %	Anteroseptal	-20.3 %	Septal	-22.1 %
	Inferoseptal	-16.8 %	Inferoseptal	-21 %	Inferior	-23.2 %
	Inferior	-23.9 %	Inferior	-20.1 %	Lateral	-23.2 %
	Inferolateral	-25.4 %	Inferolateral	-24.2 %		
	Anterolateral	-24 %	Anterolateral	-22.6 %		
RV	Anterior	-23.3 %	Anterior	-20.2 %		
	Lateral	-25.9 %	Lateral	-22.3 %		
	Inferior	-24.2 %	Inferior	-14.4 %		

Circumferential MyoStrain® Measurements



	3CH (HR: 84)	4CH (HR: 73)	2CH (HR: 83)			
LV	Basal Inferolateral	-21 %	Basal Inferoseptum	-18.8 %	Basal Inferior	-21.1 %
	Mid Inferolateral	-26.2 %	Mid Inferoseptum	-23.9 %	Mid Inferior	-22.5 %
	Apical Lateral	-26.4 %	Apical Septum	-26.2 %	Apical Inferior	-26.3 %
	Apical Cap	-19.3 %	Apical Cap	-24.2 %	Apical Cap	-22.6 %
	Apical Anterior	-20.6 %	Apical Lateral	-25 %	Apical Anterior	-24.5 %
	Mid Anteroseptum	-19.2 %	Mid Anterolateral	-26.9 %	Mid Anterior	-20.2 %
	Basal Anteroseptum	-23.2 %	Basal Anterolateral	-21.9 %	Basal Anterior	-13 %
RV	Basal Anterior	-21.1 %	Basal Lateral	-21.7 %		
	Mid Anterior	-21.3 %	Mid Lateral	-22.9 %		
			Apical Lateral	-23.2 %		

REPORT



2 | Hypertensive Heart Disease with Undiagnosed LBBB Post COVID-19

Patient history

- 72 yr Male
- Dilated Cardiomyopathy
- COVID-19 7/2020
 - Post-viral fatigue syndrome
- Arterial Hypertension
- Diabetes Mellitus
- Hyperlipidemia

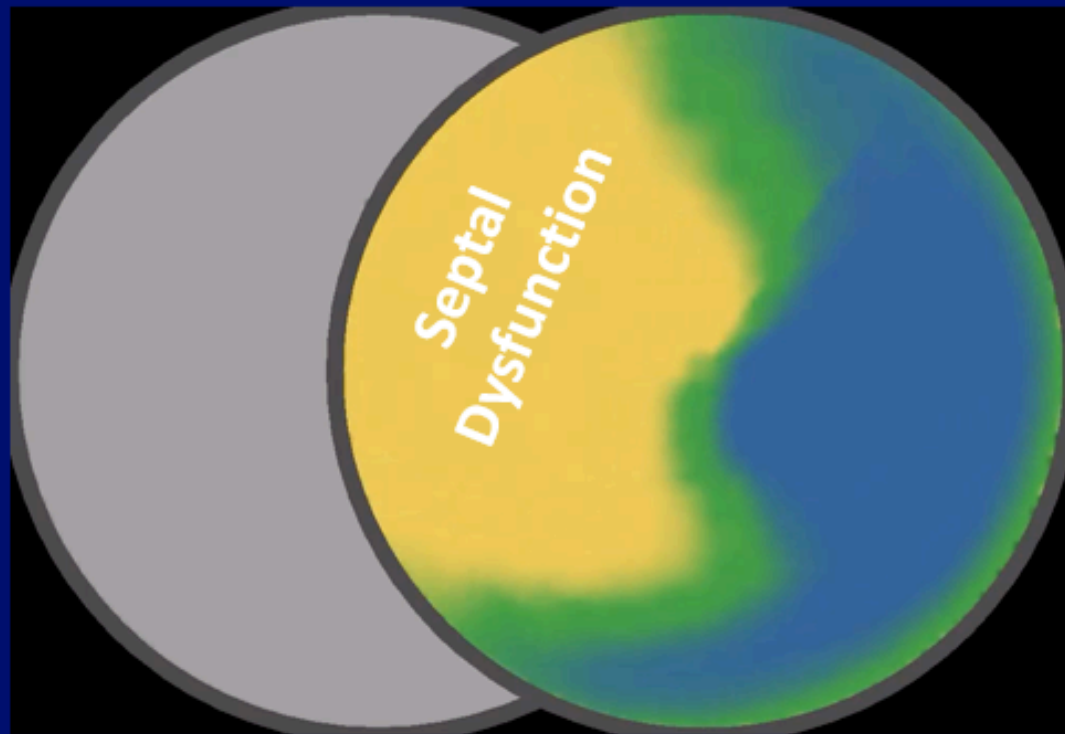
Clinical findings

- CMR LVEF – 56%
 - No myocarditis or effusion
- Abnormal Function (MyoHealth – 54%)
- Delayed Right to Left Ventricular Contraction
- Dyssynchrony Along Lateral & Anterior Wall
- No Ischemia but Heart Rate did not Increase

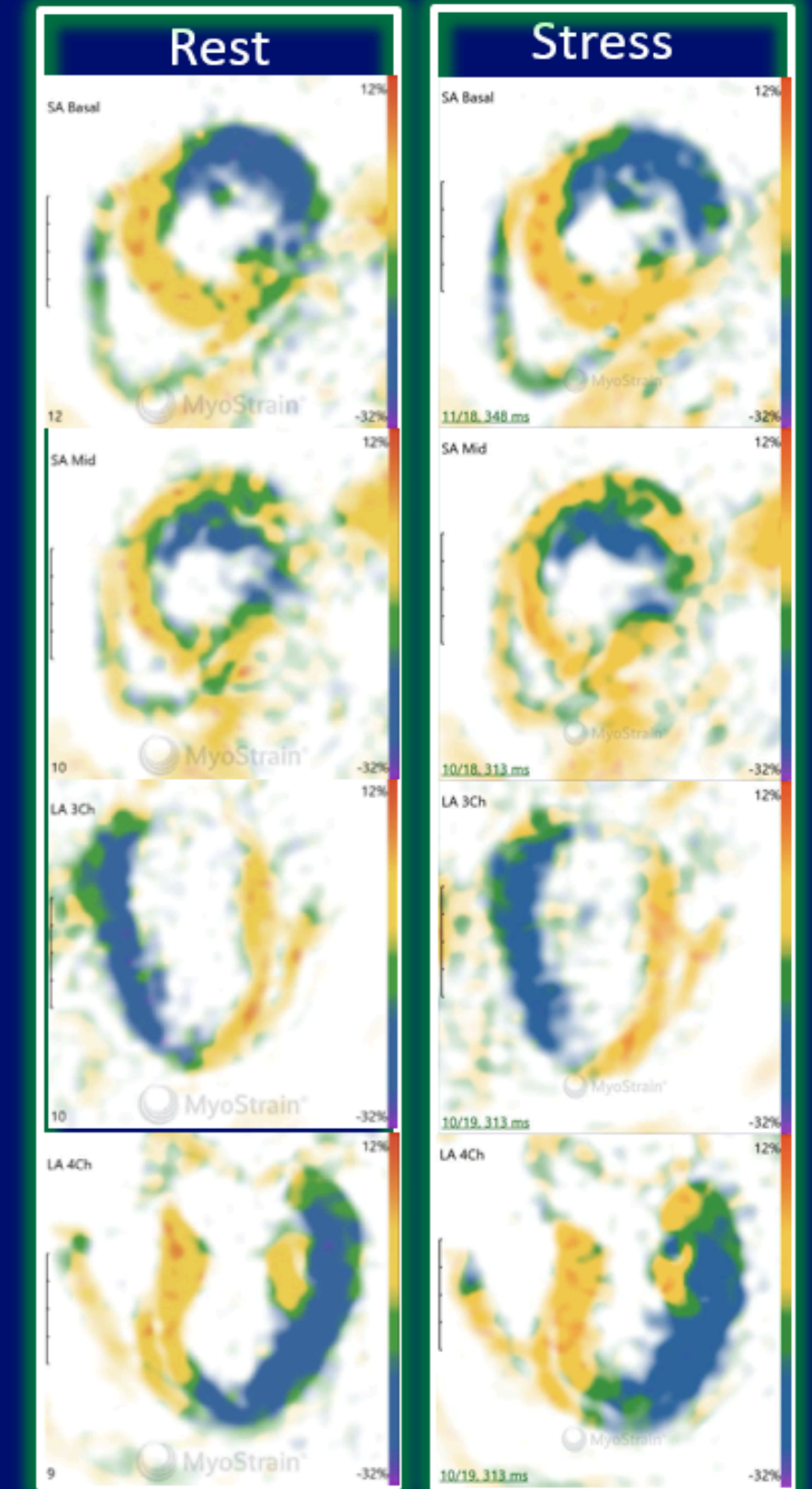
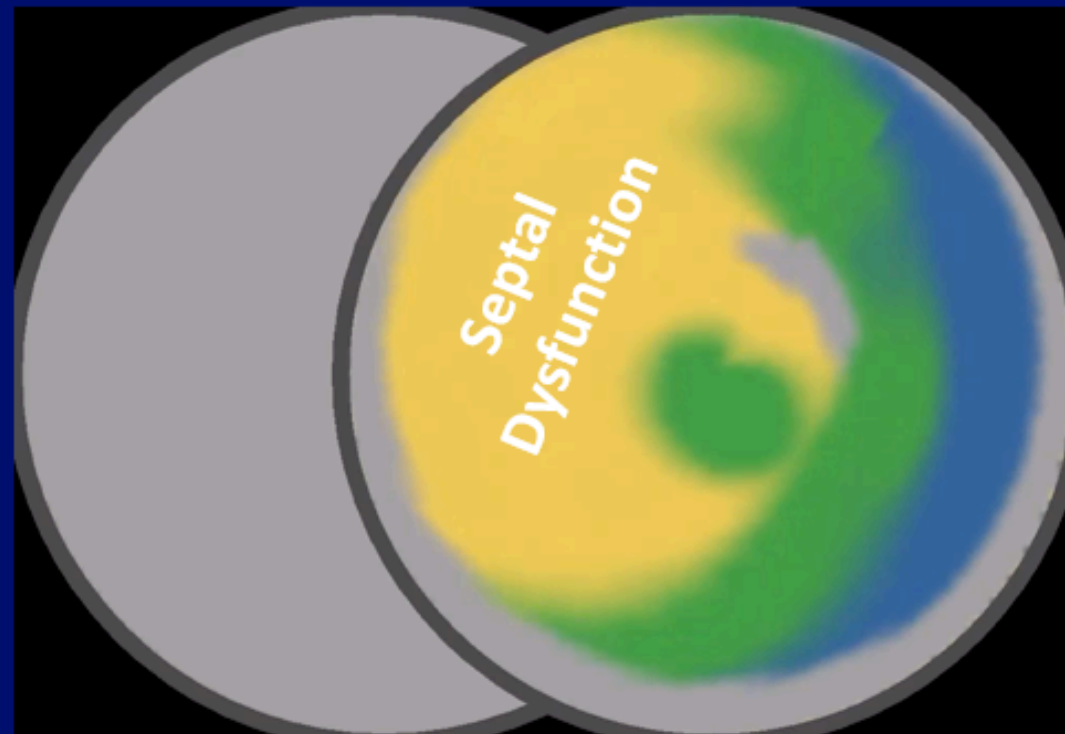
2 | Hypertensive Heart Disease with Undiagnosed LBBB Post COVID-19

MYOSTRAIN IMAGING

Circumferential



Longitudinal

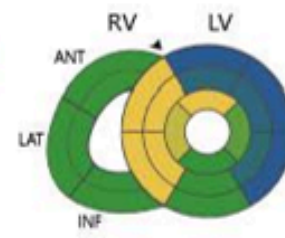
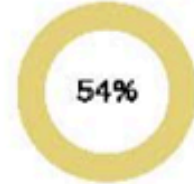

2 | Hypertensive Heart Disease with Undiagnosed LBBB Post COVID-19

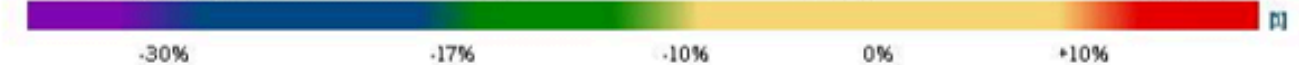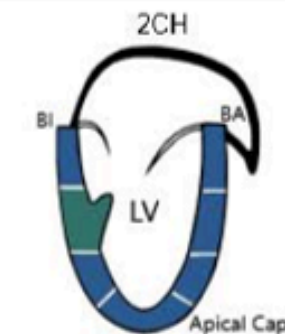
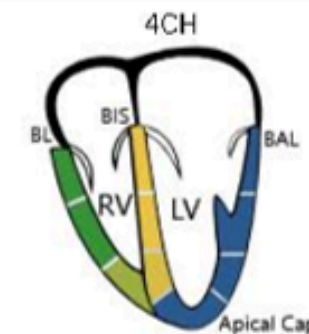
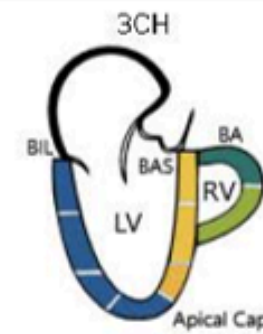
Patient: MyoSenc_14_Anonymous	ID: ID_14	Accession #:
Exam Type: NA	Height: 178.0 cm (5' 10.0")	Scan Date: 10/28/2020
Gender: M (male)	Weight: 97.0 kg (213.8 lbs)	Ordering Phys:
DOB:	BSA: 2.15 m ²	Scanning Tech:
Age: NA		Indication:

Heart at Rest


LV MyoHealth® 

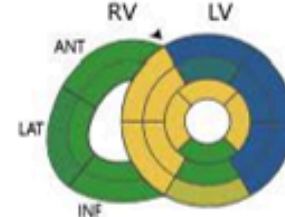
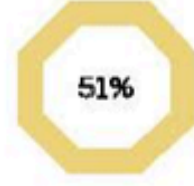

HR: B 73, M 73, A 73

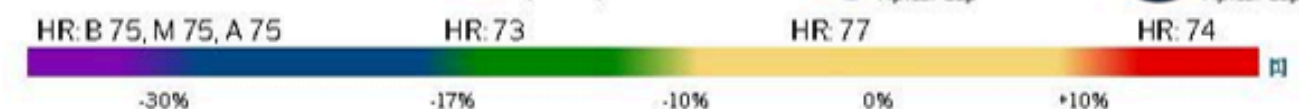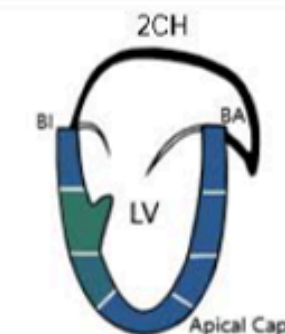
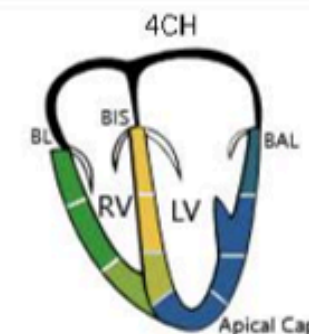
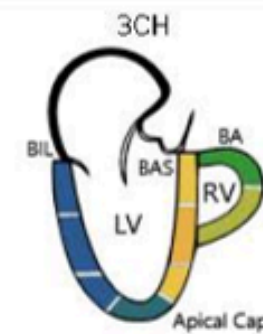


Stressed Heart

Stressed LV
MyoHealth® 

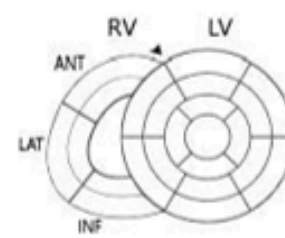


HR: B 75, M 75, A 75

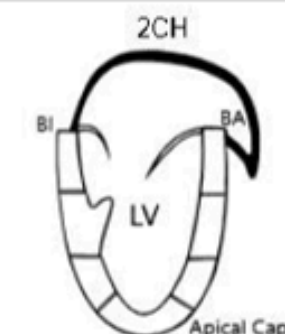
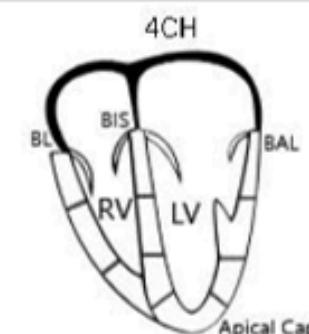
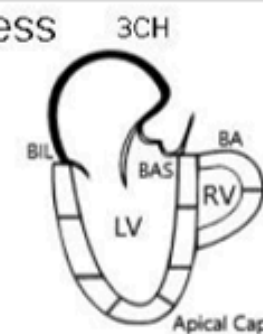


Change Between Rest and Stress

Stress Agent
Stress



ΔHR: B +2, M +2, A +2



REPORT

3 | Myocarditis Missed with Echocardiography

Patient history

- 35-year male, former smoker (10 pys)
- Body Mass Index: 29 kg/m²
- Arterial Hypertension
- Bronchial Asthma
- Osteoblastoma with enbloc spondylectomy
- Feverish Infections 12/2017 and 2/2018

Clinical findings

2/14/2018: Hospitalized for chest pain & dizziness 14 days after influenza

- Echo (TTE): LVEF – 60%
- Troponin I Normal
- NT-pro-BNP – 184 ng/L
 - Coronary Angiography: No ischemic CAD
- 24-hour Holter – Significantly increased polymorphic ventricular extrasystole
- Sartan therapy & Calcium channel blockers prescribed

Echo (TTE) – 3/22/2018

- LVEF > 55%
- Still symptomatic

Baseline CMR – 3/28/2018 (MyoHealth – 27%) - Myocarditis

- LVEF – 47%; LVEDVI – 103 ml/m²; LVESVI – 54 ml/m²; LVSVI – 49 ml/m²
- Global Hypokinesia with atypical LGE – Basal- & Mid-Inferoseptal
- Prescribed Bisoprolol 2.5 mg qd

Follow-Up CMR – 5/29/2018 (MyoHealth – 65%) – ON Bisoprolol 2.5 mg qd

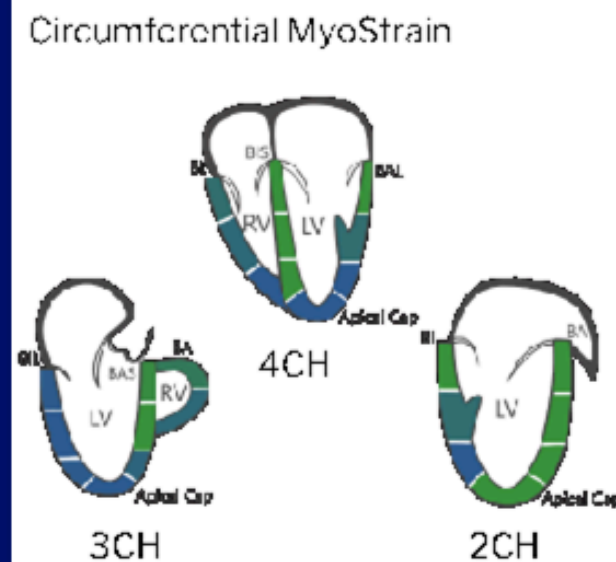
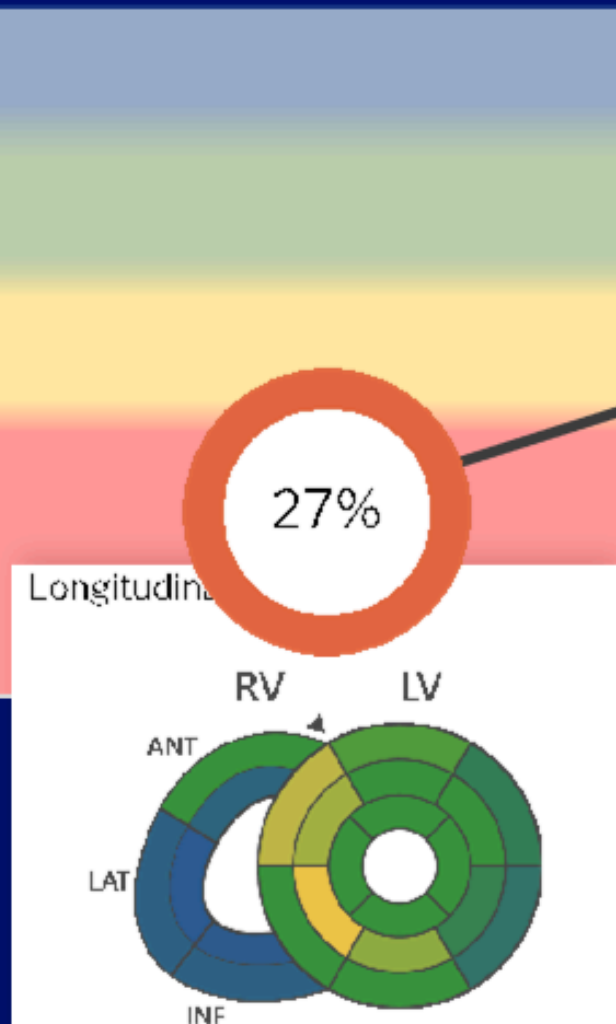
- LVEF – 55%; LVEDVI – 88 ml/m²; LVESVI – 40 ml/m²; LVSVI – 48 ml/m²

3 | Myocarditis Missed with Echocardiography

Follow Up #1
62 days

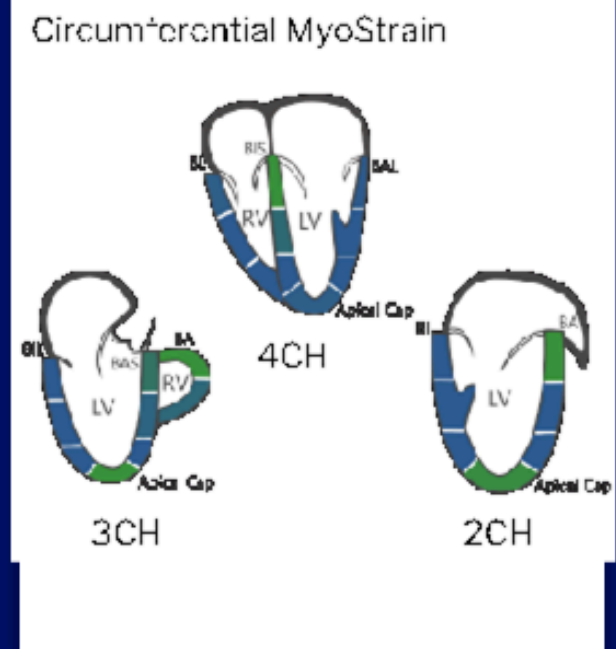
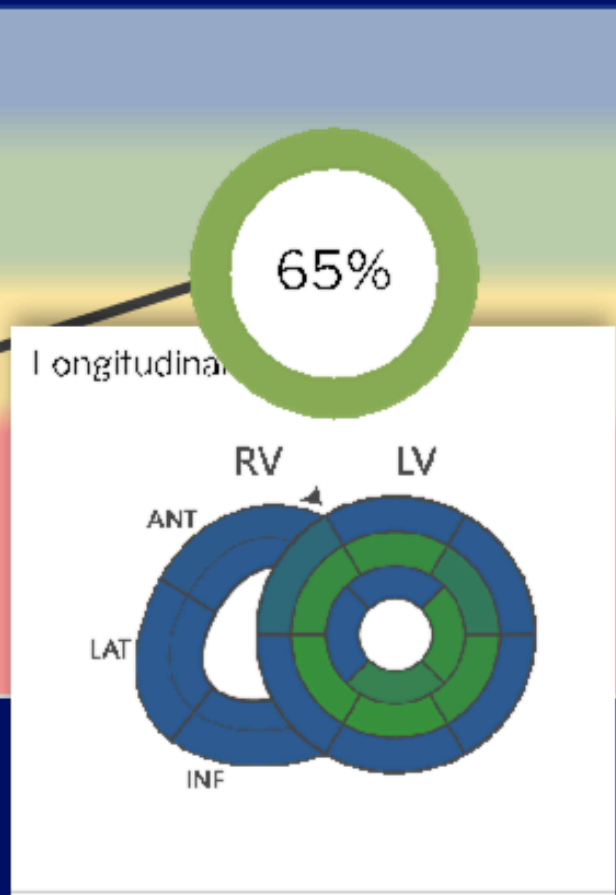
MyoHealth (%)
100%
90%
80%
70%
60%
50%
40%
30%
20%
10%
0%

Baseline



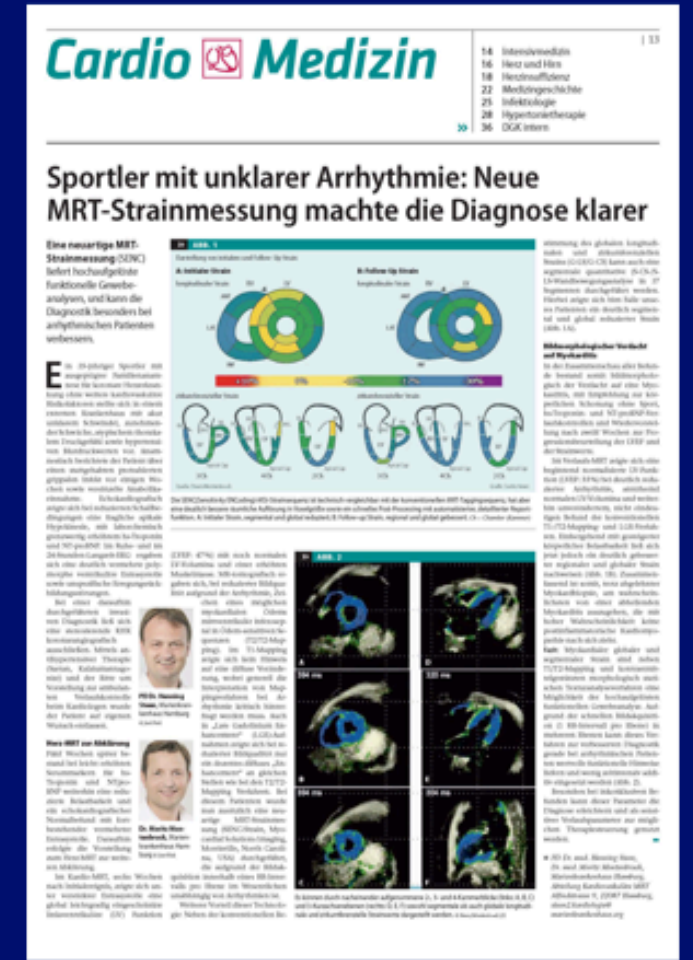27%

62 days



65%

MYOSTRAIN IMAGING

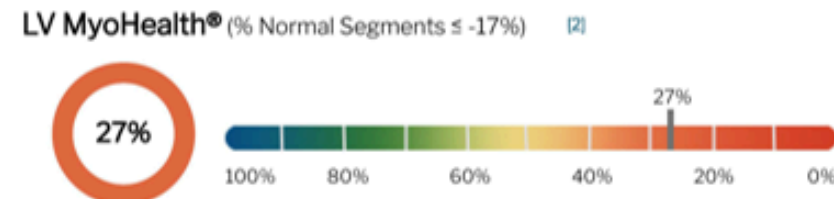


3 | Myocarditis Missed with Echocardiography

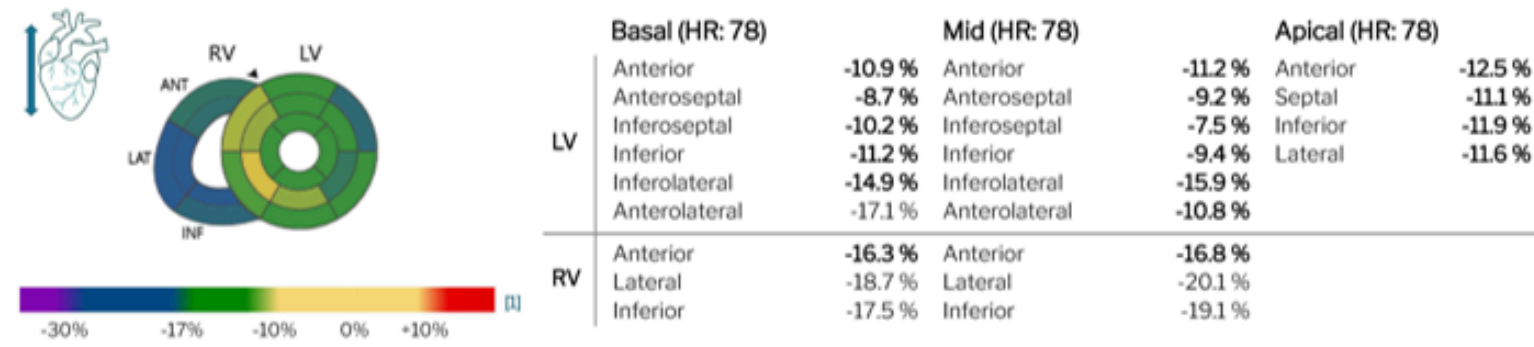
Patient: SM82_280318 **ID:** Anonymized **Accession #:**
 Exam Type: MR ZPM Herz Perfusion Height: 184.0 cm (6' 0.4") Scan Date: 03/28/2018
 Gender: Weight: 99.0 kg (218.2 lbs) Ordering Phys:
 DOB: BSA: 2.22 m2 Scanning Tech:
 Age: NA Indication:

MyoStrain® Results

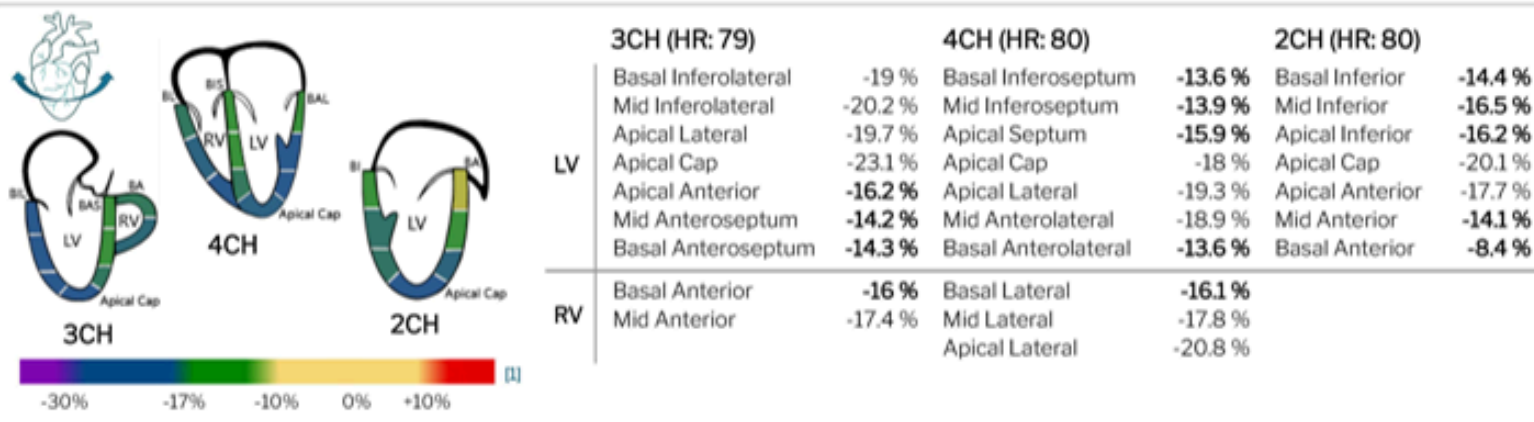
LV Dysfunctional Segments
 (37/37 Segments Analyzed)
 Number of Segments >-10%: 5
 Number of Segments >-17%: 27



Longitudinal MyoStrain® Measurements



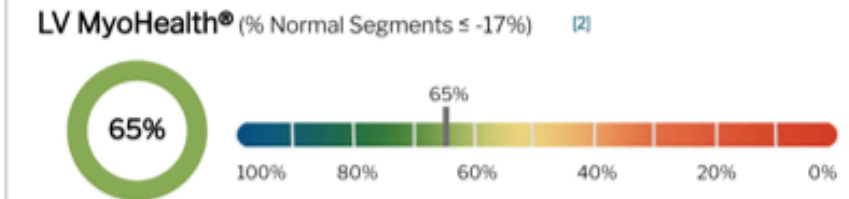
Circumferential MyoStrain® Measurements



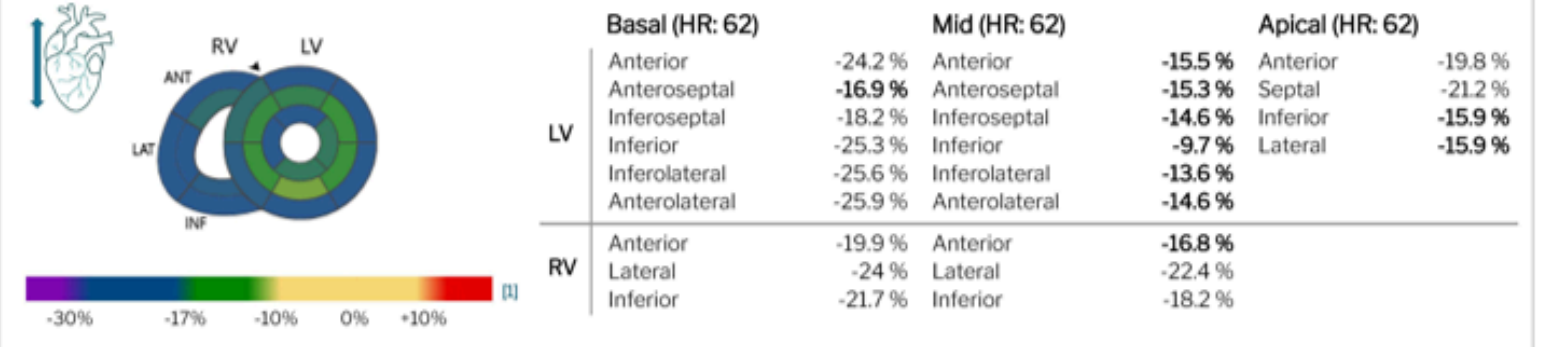
Patient: SM82_290518 **ID:** Anonymized **Accession #:**
 Exam Type: MR ZPM Herz Perfusion Height: 184.0 cm (6' 0.4") Scan Date: 05/29/2018
 Gender: Weight: 90.0 kg (198.4 lbs) Ordering Phys:
 DOB: BSA: 2.13 m2 Scanning Tech:
 Age: NA Indication:

MyoStrain® Results

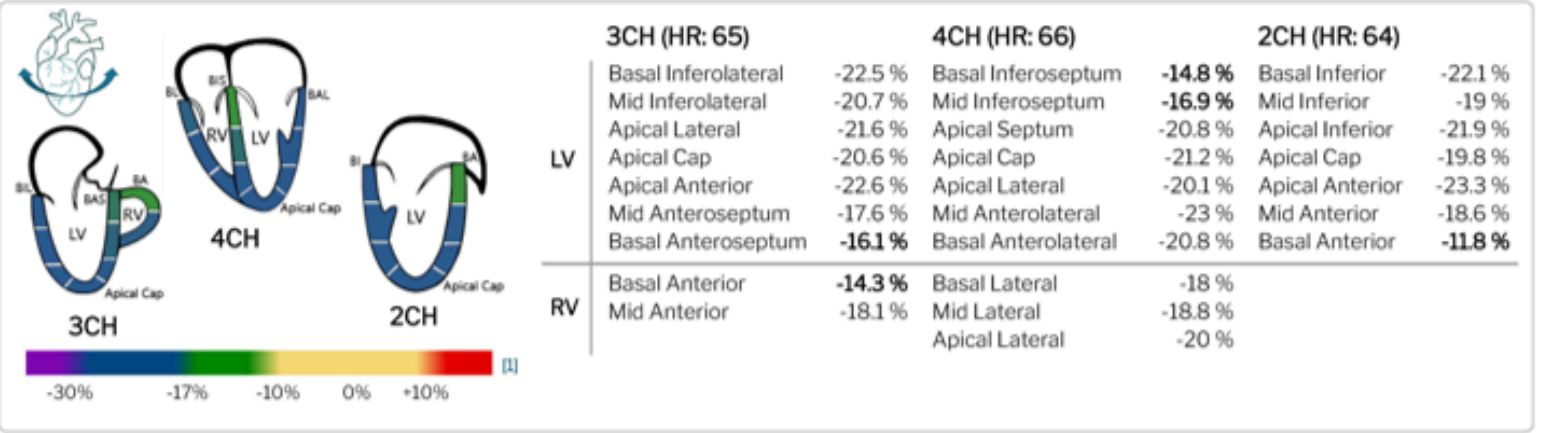
LV Dysfunctional Segments
 (37/37 Segments Analyzed)
 Number of Segments >-10%: 1
 Number of Segments >-17%: 13



Longitudinal MyoStrain® Measurements



Circumferential MyoStrain® Measurements



4 | Peri-Myocarditis with Improving Myocardial Function

Patient history

- 40-year Male, former smoker (5 pys)
- Body Mass Index – 32 kg/m²
- Recurrent Infections 12/2018 including influenza
- Excluded Coronary Artery Disease
- Troponin 4.6 ng/ml on 1/2/19
- Hyperthyroidism
- Sleep Apnea

Clinical findings

1/7/2019: Baseline – Acute Peri-Myocarditis

- NYHA III
- Abnormal MyoHealth (54%) with Slight Dyssynchrony
- LVEF = 62%; RVEF = 62%
- LVEDVI = 72 ml/m²; LVESVI = 28 ml/m²
- MAPSE = 11 mm; TAPSE = 30 mm
- Septal WT = 11 mm; Lateral WT = 8 mm
- Infarct-Atypical LGE spotty basal to apical lateral
- Transmural myocardial edema BIL / MIL / MAL

3/21/2019: CMR Follow-Up (73 days) – Healing Peri-Myocarditis

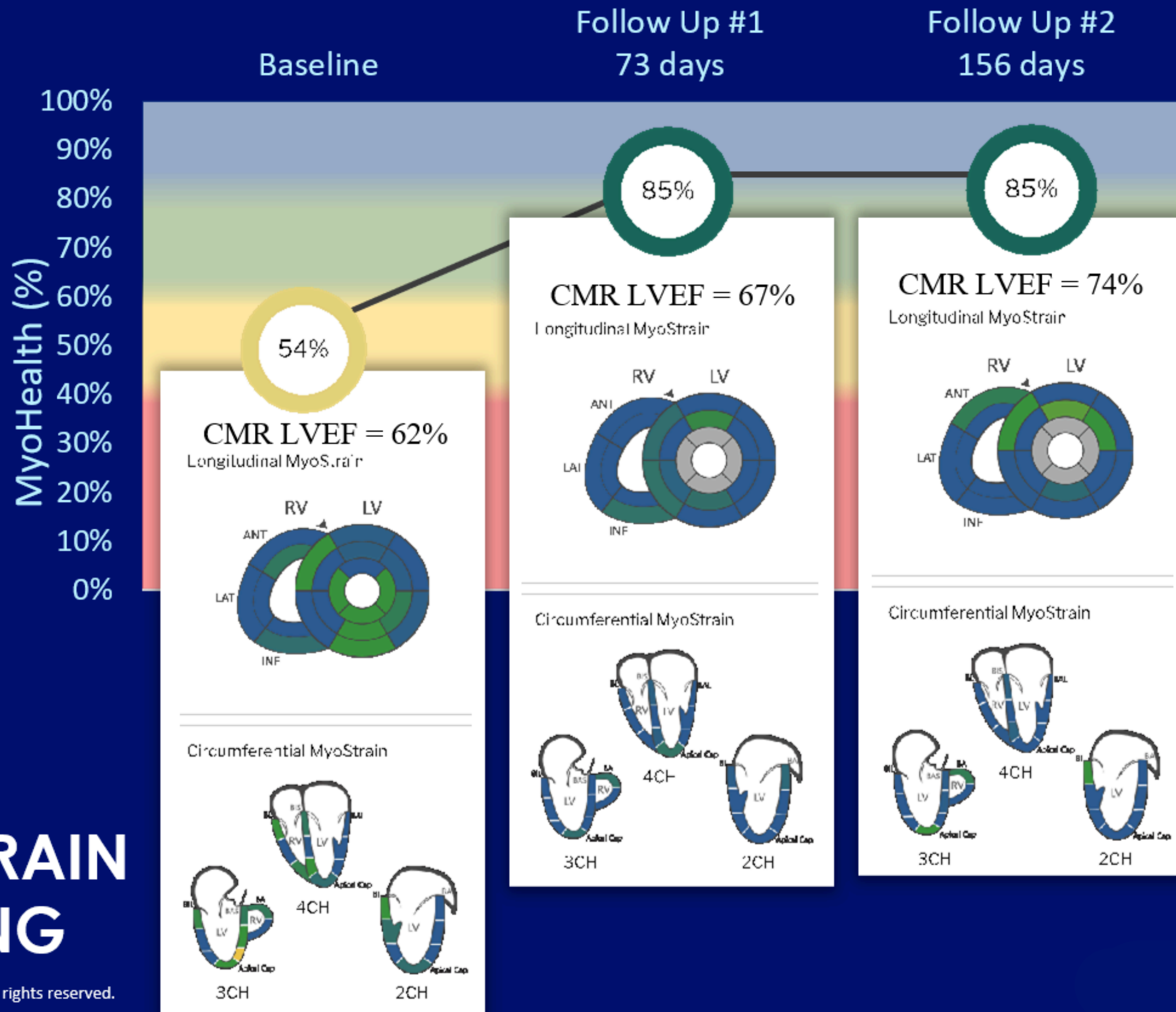
- NYHA II
- Normal MyoHealth (85%) with Slight Dyssynchrony
- LVEF = 67%; RVEF = 67%
- LVEDVI = 72 ml/m²; LVESVI = 22 ml/m²
- MAPSE = 10 mm; TAPSE = 28 mm
- Septal WT = 9 mm; Lateral WT = 6 mm
- Infarct-Atypical LGE regressed but spotty BIL / MIL / MAL

6/12/2019: CMR Follow-Up (156 days) – Healed Peri-Myocarditis

- NYHA I-II
- Normal MyoHealth (85%) with Slight Dyssynchrony
- LVEF = 74%; RVEF = 62%
- LVEDVI = 73 ml/m²; LVESVI = 19 ml/m²
- MAPSE = 10 mm; TAPSE = 30 mm
- Septal WT = 8 mm; Lateral WT = 5 mm
- Further Regressed Infarct-Atypical LGE BIS / BI / BIL

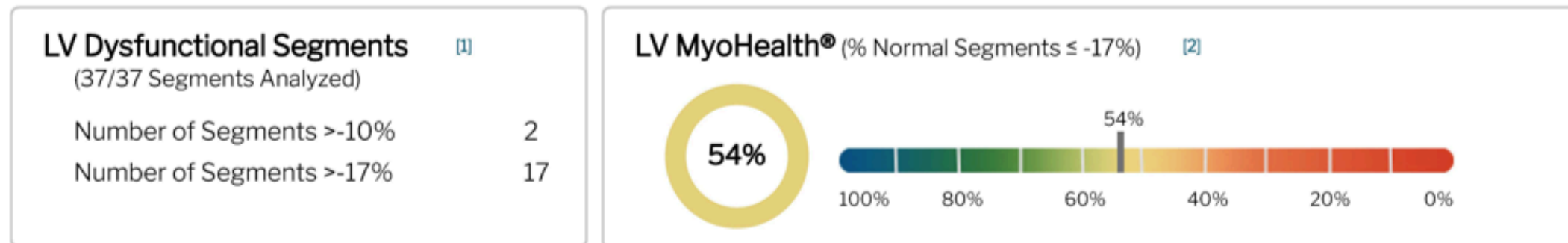


4 | Peri-Myocarditis with Improving Myocardial Function

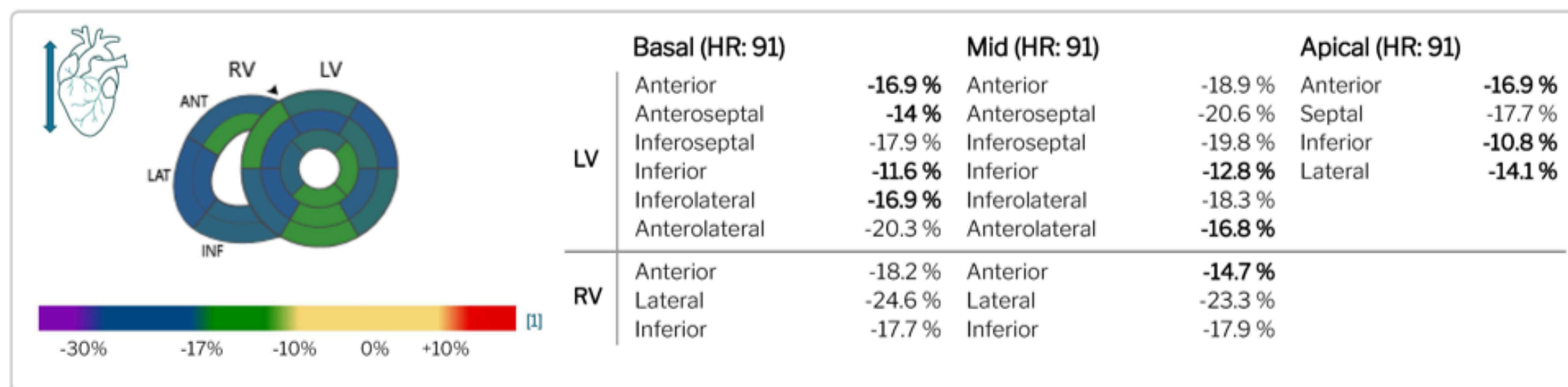


**MYOSTRAIN
IMAGING**

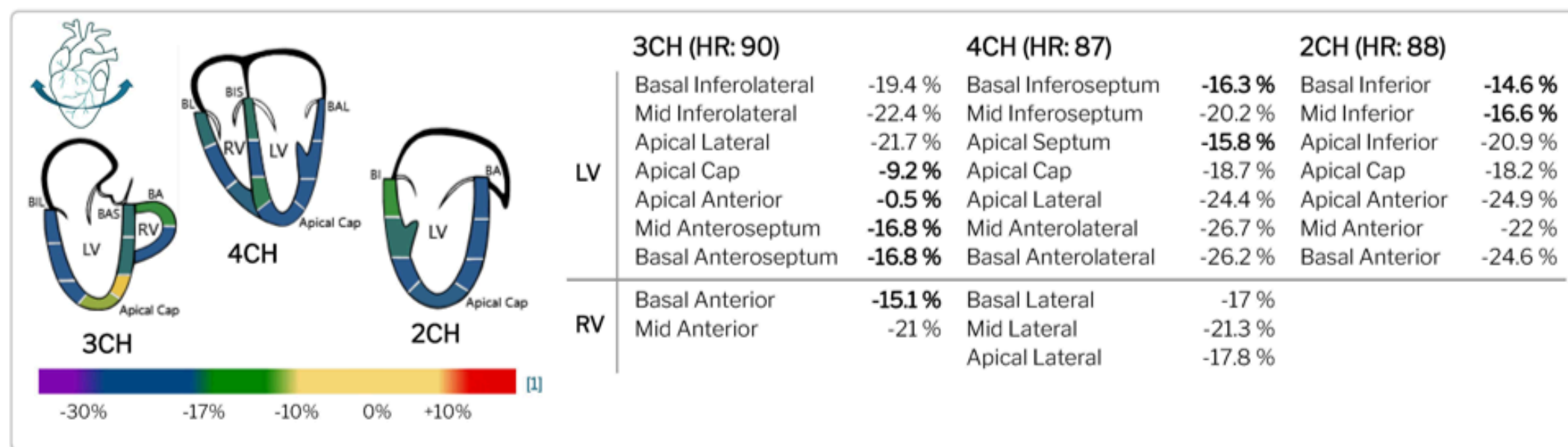
4 | Peri-Myocarditis with Improving Myocardial Function



Longitudinal MyoStrain® Measurements



Circumferential MyoStrain® Measurements



REPORT

5 | Dilated Cardiomyopathy Treated with Immunosuppressive & Entresto

Clinical findings

Patient history

- 52 yr Male Smoker (45 yrs)
- Dilated Cardiomyopathy
- Pulmonary Hypertension
- Moderate MV & TV Regurgitation
- 1-vessel CAD (RCX)

Baseline CMR Exam

- NYHA III-IV
- Abnormal MyoHealth with Dyssynchrony
- Severe Global Hypokinesia w/ Dyssynchrony
- LVEDVI – 201 ml/m²; LVESVI – 184 ml/m²
- Dilated Cardiomyopathy (Inflammatory)
- Mild LVNC
- Pericardial Effusion (100 ml)
- Infarct-Typical LGE Apical Septal

Follow-Up #1 (120 days)

- NYHA II
- Improved but Abnormal MyoHealth with Dyssynchrony
- Immunosuppressive Therapy
- Started Entresto 49/51 mg (1-0-1)
- LVEDVI – 120 ml/m²; LVESVI – 82 ml/m²

Follow-Up #2 (219 days)

- NYHA II
- Improved but Abnormal MyoHealth with Dyssynchrony
- LVEDVI – 111 ml/m²; LVESVI – 66 ml/m²

Follow-Up #3 (225 days)

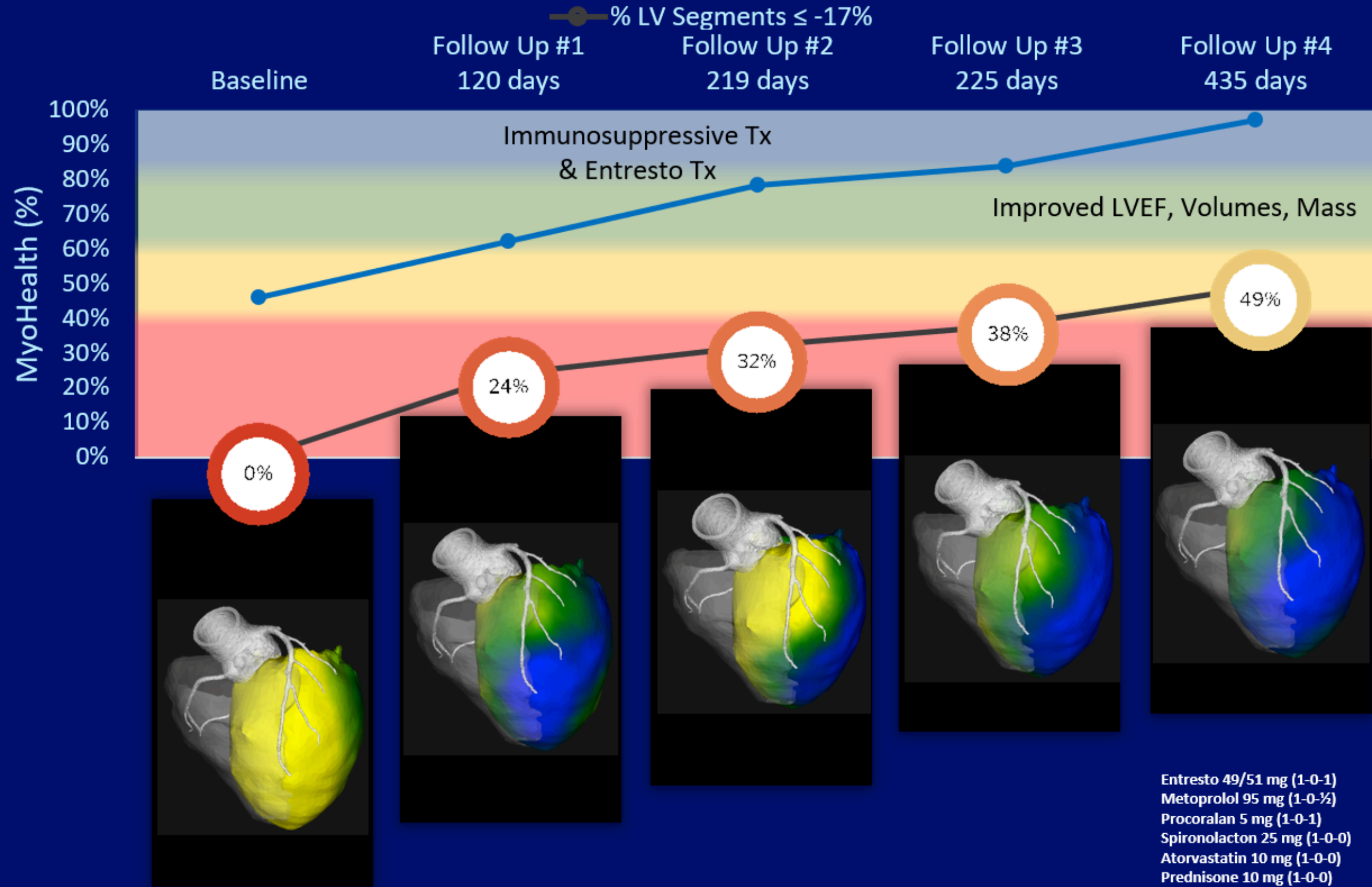
- NYHA I-II
- Improved but Abnormal MyoHealth with Dyssynchrony

Follow-Up #4 (435 days)

- NYHA I-II
- Improved but Abnormal MyoHealth with Dyssynchrony
- LVEDVI – 104 ml/m²; LVESVI – 50 ml/m²



5 | Dilated Cardiomyopathy Treated with Immunosuppressive & Entresto



**MYOSTRAIN
IMAGING**

Entresto 49/51 mg (1-0-1)
 Metoprolol 95 mg (1-0-½)
 Procoralan 5 mg (1-0-1)
 Spironolacton 25 mg (1-0-0)
 Atorvastatin 10 mg (1-0-0)
 Prednisone 10 mg (1-0-0)
 Azathioprin 100 mg (1-0-0)

6 | Hypertensive Heart Disease with Moderately Reduced Ejection Fraction

Patient history

- 62-year Female, Former Smoker (15 yrs),
- Body Mass Index – 25 kg/m²
- NYHA II, Hypercholesterolemia,
- Coronary Artery Disease (50% LAD – 1.5 years Prior)
- LBBB, Moderate MV & TV Regurgitation
- MyoHealth = 38% with right to left delay and apical to basal depolarization

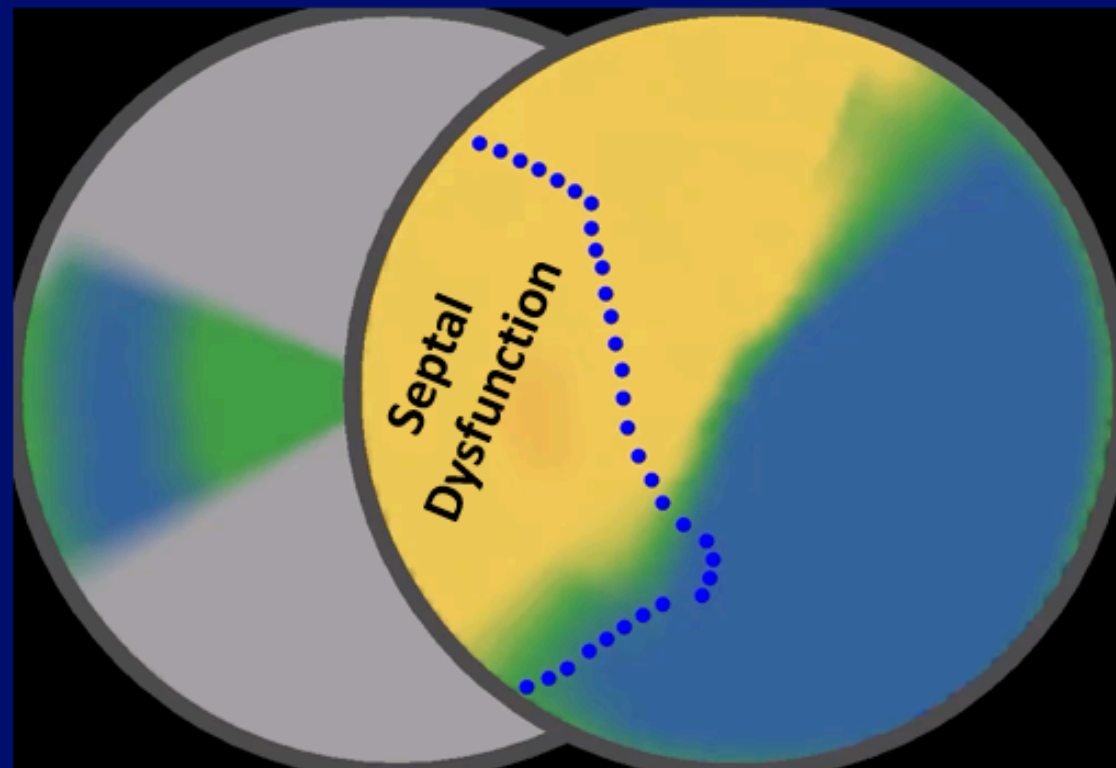
Clinical findings

- LVEF – 45%, LVEDVI – 84 ml/m², LVESVI – 46 ml/m², LVSVI – 38 ml/m²
- MAPSE – 9 mm, Septal WT – 11 mm, Lateral WT – 6 mm, NO LGE
- RVEF – 57%, RVSVI – 34 ml/m², TAPSE – 20 mm
- Ascending Aorta – 34 mm, LA Diameter – 32 mm
- Pulmonary Trunk Diameter – 28 mm

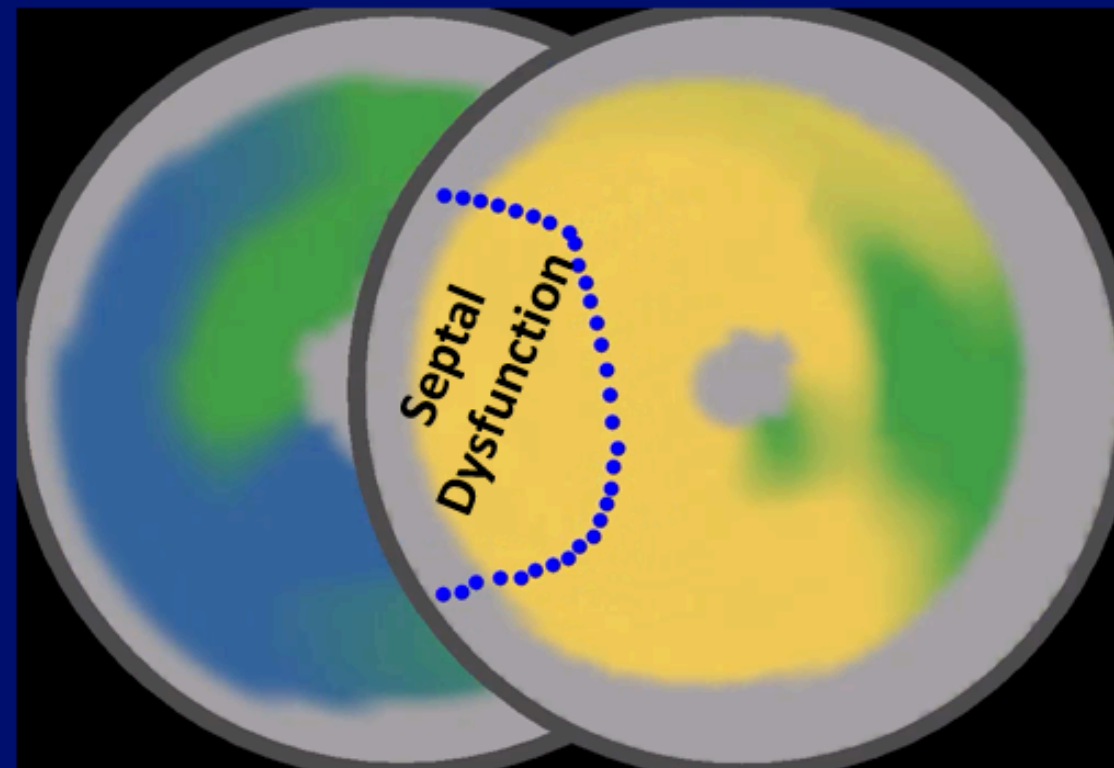
6 | Hypertensive Heart Disease with Moderately Reduced Ejection Fraction

MYOSTRAIN IMAGING

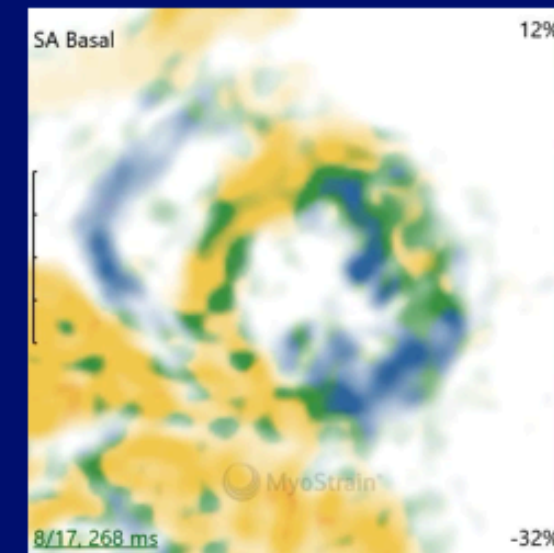
Circumferential



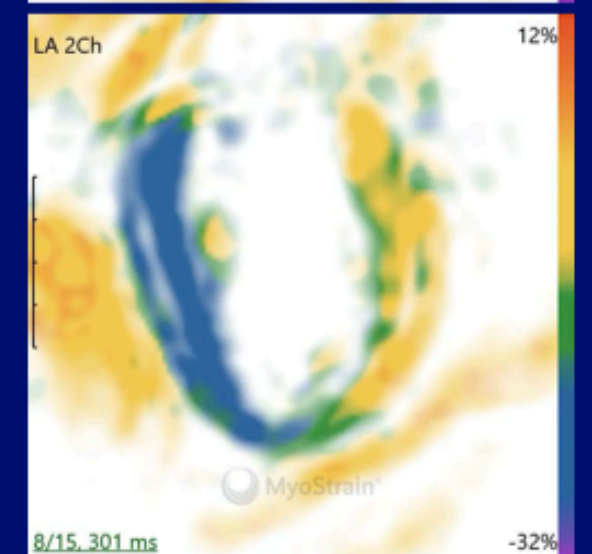
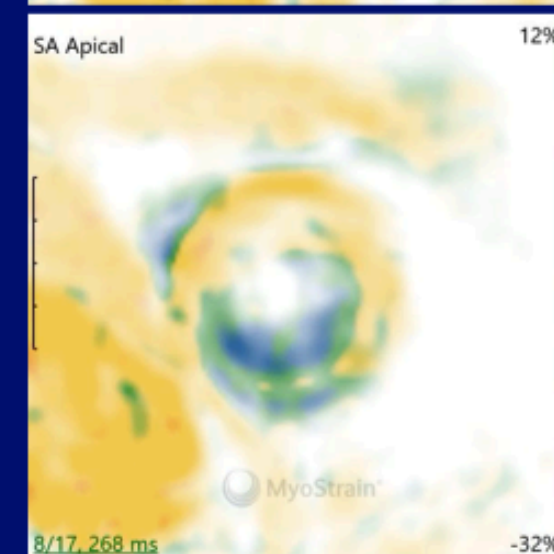
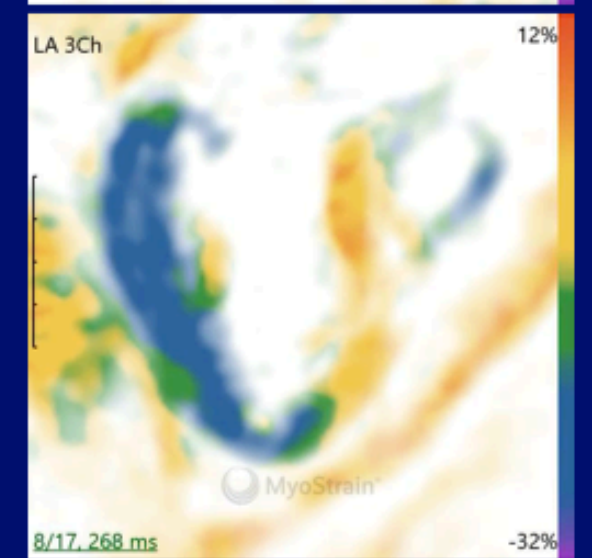
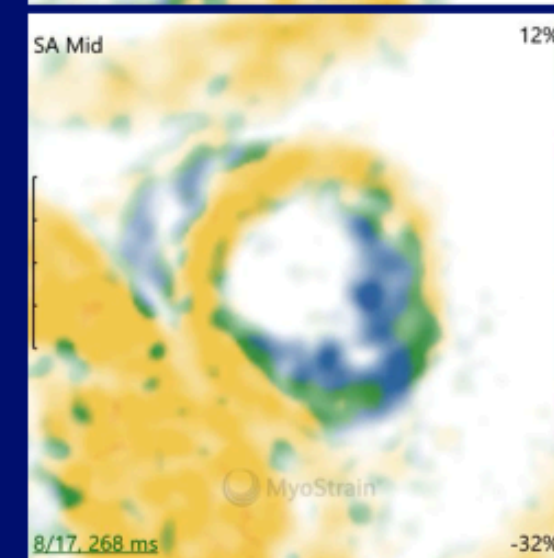
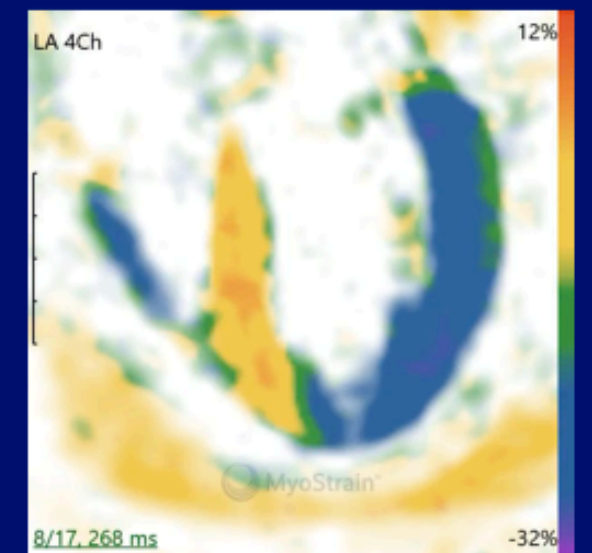
Longitudinal



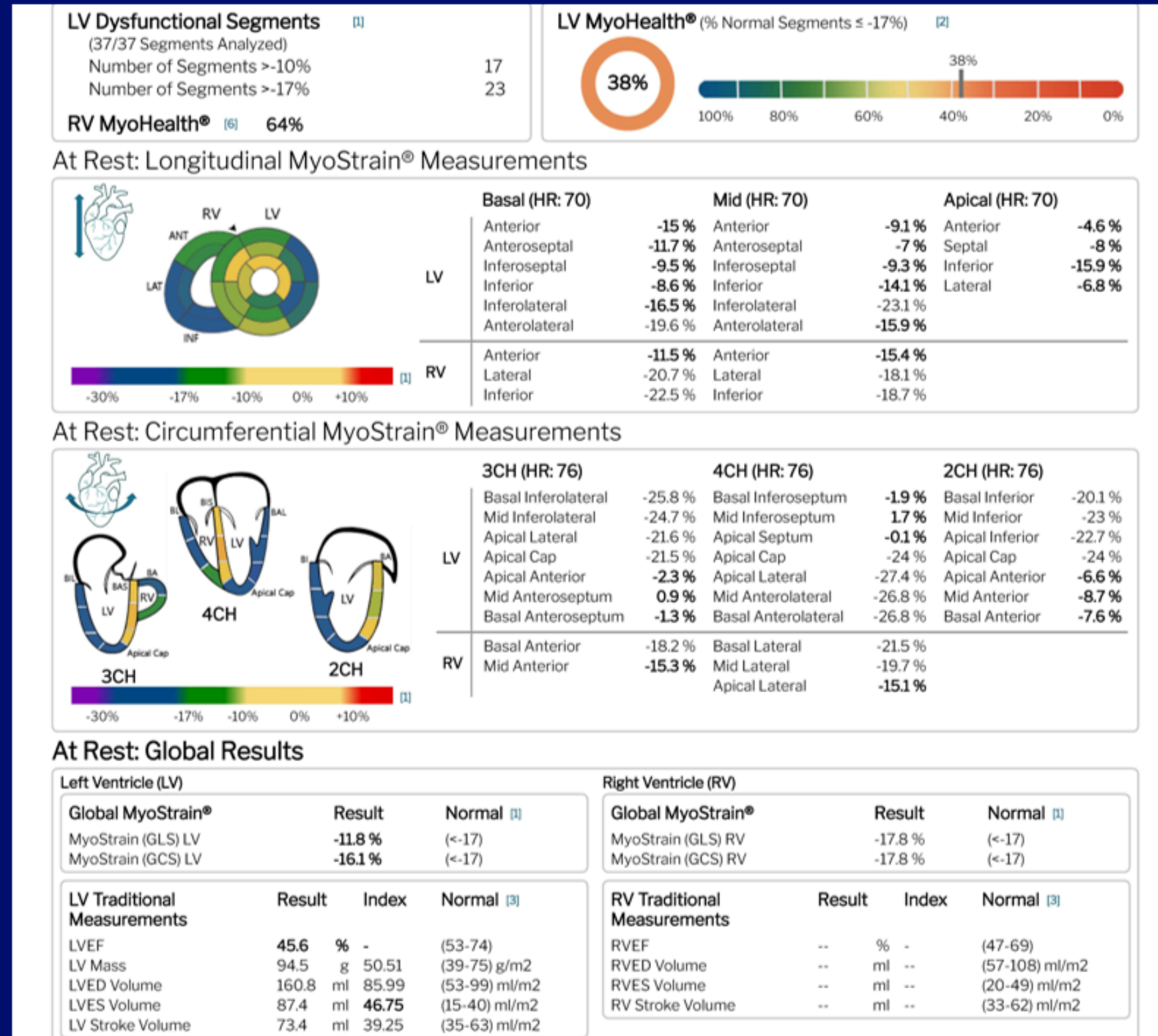Longitudinal



Circumferential



6 | Hypertensive Heart Disease with Moderately Reduced Ejection Fraction



REPORT

7 | Right Heart Dysfunction in Severe Pulmonary Hypertension

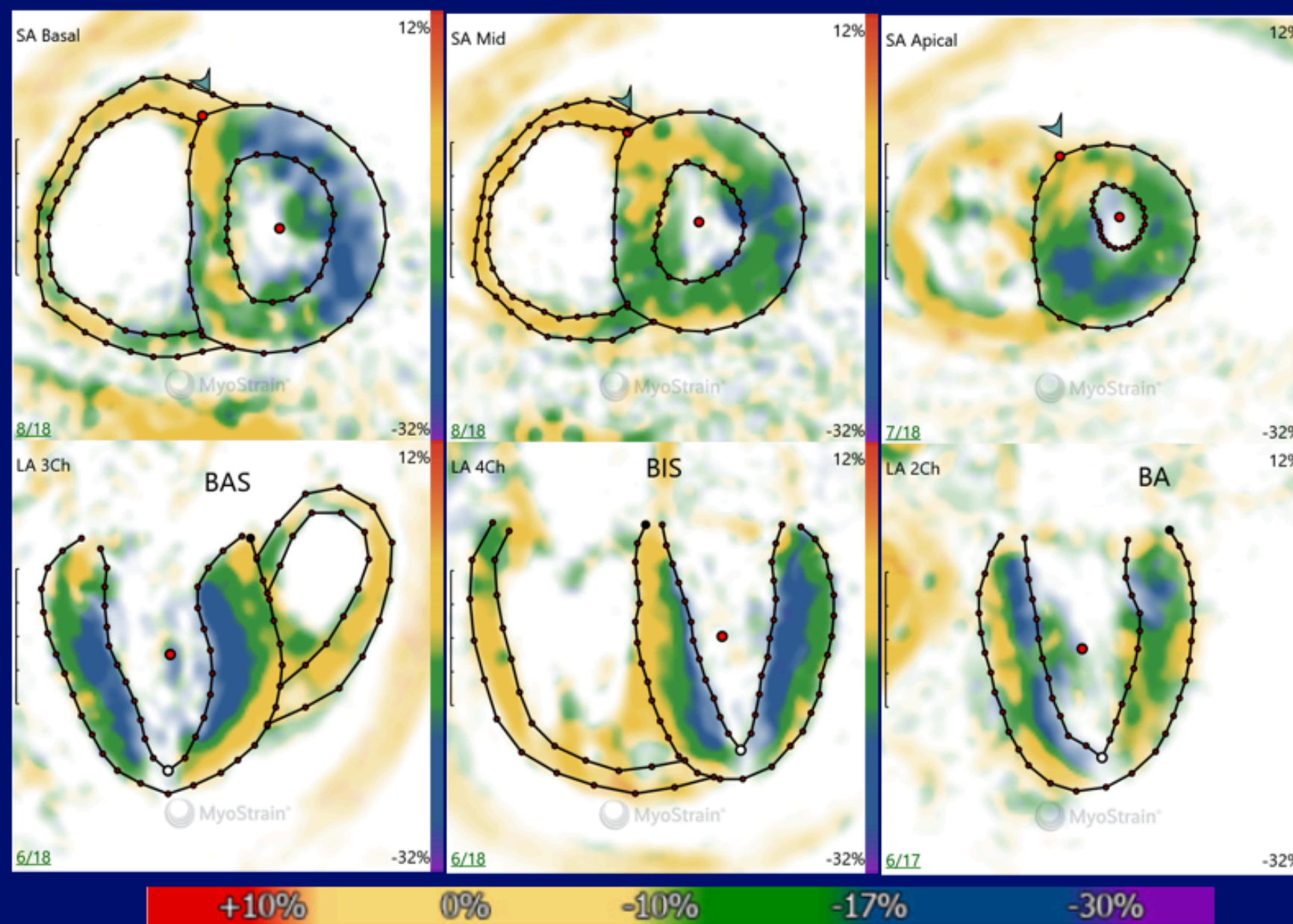
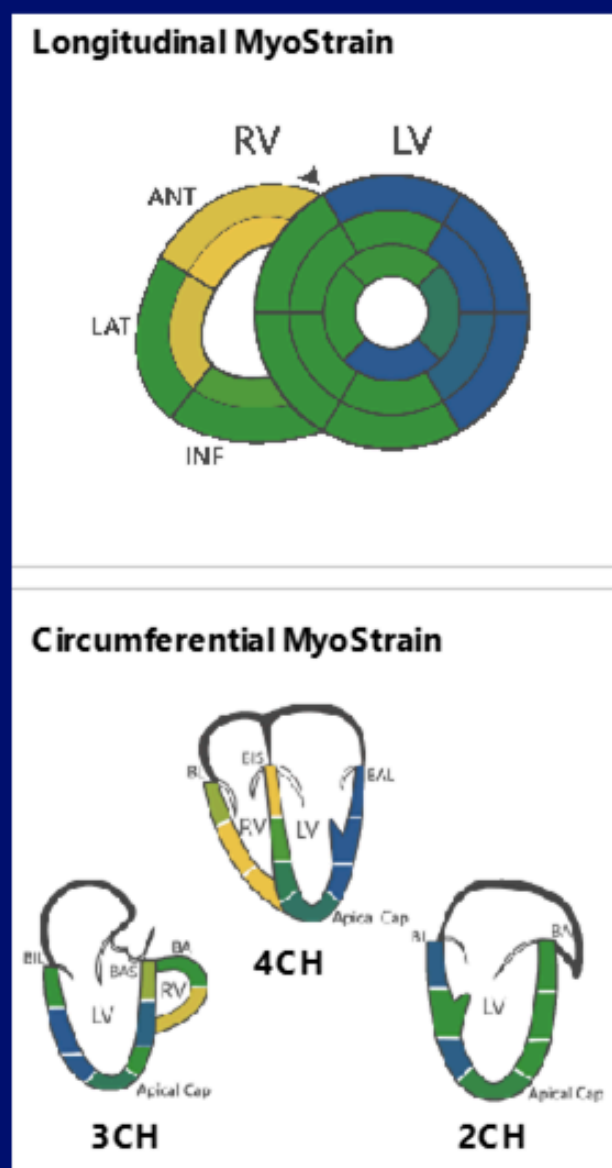
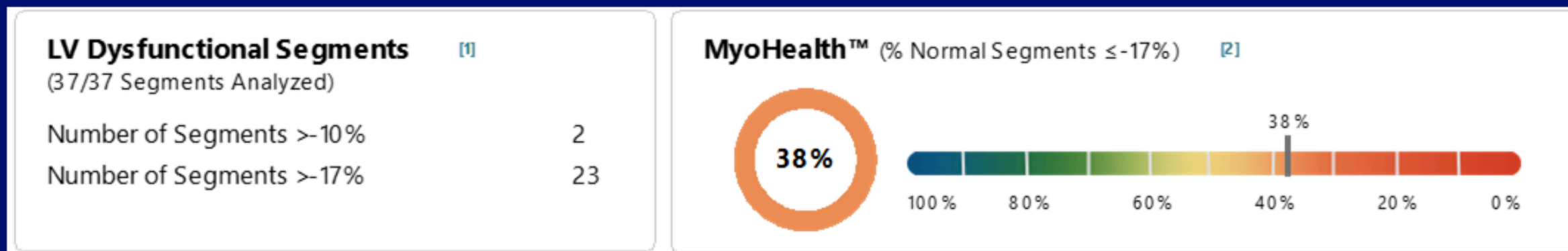
Patient history

- 60 yr Male, Former Smoker (since 1994)
- NYHA III
- Body Mass Index – 31 kg/m²
- Body Surface Area – 2.2 m²
- Arterial Hypertension
- Diabetes Mellitus
- Hypercholesterolemia
- High-grade Pulmonary Arterial Hypertension
- Home Oxygen Therapy
- Coronary Artery Disease (PCI with stent 2015)

Clinical findings

- MyoStrain CMR – January 24, 2018
- Chronic RV loading with RV hypertrophy
- MyoHealth – 38%; Substantial Dyssynchrony
 - LVEF – 50%
 - LVEDVI – 48 ml/m²; LVESVI – 24 ml/m²
 - LV Stroke Volume Index – 24 ml/m²
 - MAPSE – 9 mm
 - Septal Wall Thickness – 13 mm
 - Lateral Wall Thickness – 8 mm
- RVEF – 27%
 - RVEDVI – 94 ml/m²; RVSVI – 68 ml/m²
 - RV Stroke Volume Index – 26 ml/m²
 - TAPSE – 13 mm
 - RV Hypertrabecularization
- No dyssynchrony recorded with CINE
- Left Atrial Diameter – 37 mm
- Left Atrial Area Index – 10 cm²/m²

7 | Right Heart Dysfunction in Severe Pulmonary Hypertension



**MYOSTRAIN
IMAGING**

8 | Apical Hypertrophic Cardiomyopathy

Patient history

- 69-year Female, Smoker
- Body Mass Index – 17 kg/m²
- Hypercholesterolemia
- ECG signs of hypertrophy
- Troponin positive
- Excluded coronary artery disease

Clinical findings

MyoStress – October 5, 2017

- NYHA II
- Apical HCM
- Abnormal MyoHealth (60%), No Dyssynchrony
 - Apical Dysfunction
- CMR LVEF – 56% RVEF – 69%
- LVEDVI – 66 ml/m² LVESVI – 29 ml/m²
- LV Mass Index – 55 g/m²
- Septum WT – 8 mm Lateral WT – 5 mm
- MAPSE – 9 mm TAPSE – 13 mm
- Left Atrium Diameter – 19 mm LA Area – 11 cm²/m²
- Atypical LGE MAL / AA / AS / AI / AL / AC – LGE score – 1.1

Late Follow-Up – June 19, 2020 (988 days)

- No Adverse Events
- Prescribed Statins December 2019

8 | Apical Hypertrophic Cardiomyopathy

MYOSTRAIN IMAGING

LV Dystfunctional Segments (37/37 Segments Analyzed)

Number of Segments > 10%: 7

Number of Segments > -17%: 15

MyoHealth (60% Normal Segments ≤ -17%)

At Rest: Segmental MyoStrain® Measurements

Longitudinal MyoStrain

	Basal	Mid	Apical
LV	Anterior: 23.4%	Anterior: 14.1%	Anterior: 3.7%
	Anteroseptal: -18.8%	Anteroseptal: -23.5%	Septal: -10.2%
	Inferoseptal: -17.6%	Inferoseptal: -21.2%	Inferior: -13.4%
	Inferior: -23.6%	Inferior: -23.6%	Lateral: -9.7%
	Introlateral: 23.8%	Introlateral: 19%	
	Anterolateral: -24.2%	Anterolateral: -9.6%	
RV	Anterior: -13.3%	Anterior: -21.3%	
	Lateral: -16.6%	Lateral: -22.8%	
	Inferior: -21.1%	Inferior: -21.6%	

Circumferential MyoStrain

	3CH	4CH	2CH
LV	Basal Introlateral: 23.3%	Basal Introseptum: 15.7%	Basal Anterior: 17.7%
	Mic Introlateral: 24.4%	Mid Introseptum: 20.3%	Mid Anterior: 19.1%
	Apical Lateral: -15.1%	Apical Septum: -10.7%	Apical Inferior: -10.3%
	Apical Cap: -7.9%	Apical Cap: -8.7%	Apical Cap: -8.1%
	Apical Anterior: 6.9%	Apical Lateral: 19.4%	Apical Anterior: 14.8%
	Mic Anteroseptum: 20.4%	Mid Anterolateral: 23.3%	Mid Anterior: 20.6%
	Basal Anteroseptum: -24.1%	Basal Anterolateral: -24.2%	Basal Anterior: -19.2%
RV	Basal Anterior: -15.7%	Basal Lateral: -9.3%	
	Mic Anterior: -21.9%	Mid Lateral: -9.1%	
		Apical Lateral: -12.5%	

Global MyoStrain®	Result	Normal (z)	Traditional Measurements	Result	Index	Normal (z)
MyoStrain (GLS) LV	-16.5%	(<-17)	LVEF	63.2%	-	(53-74)
MyoStrain (GCS) LV	-16.8%	(<-17)	LV Mass	83.3 g	58.25	(39-75) g/m2
MyoStrain (GLS) RV	-19.4%	(<-17)	LV ED Volume	117.7 ml	82.31	(53-99) ml/m2
MyoStrain (GCS) RV	-17.9%	(<-17)	LVES Volume	43.4 ml	30.35	(15-40) ml/m2
			LV Stroke Volume	74.3 ml	51.96	(35-63) ml/m2

9 | Hypertrophic Obstructive Cardiomyopathy

Patient history

- 49-year female, smoker (35 yrs)
- BMI: 21 kg/m²; BSA: 1.56 m²
- Arterial Hypertension
 - Significant asymmetric septal stress concentric hypertrophy
 - Septal WT – 17 mm; Lateral WT – 9 mm
 - Left atrial dilation – 35 mm (LA Area Index: 17 cm²/m²)
 - Ascending aorta diameter – 31 mm
- Hypercholesterolemia
- Moderate mitral & tricuspid valve regurgitation
- ECG – T-negative in leads I, II, III

Clinical findings

Perfusion CMR with MyoStress (Adenosine) - HOCM

- NYHA I-II
- MyoHealth – 27% (0 suspected ischemic segments)
- SAM with reduced LVOT area (obstruction during tachycardia)
- Giant Papillary Muscles
- LVEF – 55%; MAPSE – 8 mm; Mass Index – 83 g/m²;
 - LVEDVI – 83 ml/m²; LVESVI – 38 ml/m²; LVSVI – 45 ml/m²
- RVEF – 60%; TAPSE – 20 mm
 - RVEDVI – 63 ml/m²; RVESVI – 25 ml/m²; RVSVI – 39 ml/m²
- Infarct-atypical LGE: aLGE score – 1.24
 - BAS / BIS / MAS / MIS
- Perfusion defects: PD score – 1.35
 - BAS / BIS / MIS / MI / AA / AS (25-50%)

Post-Imaging Follow-Up

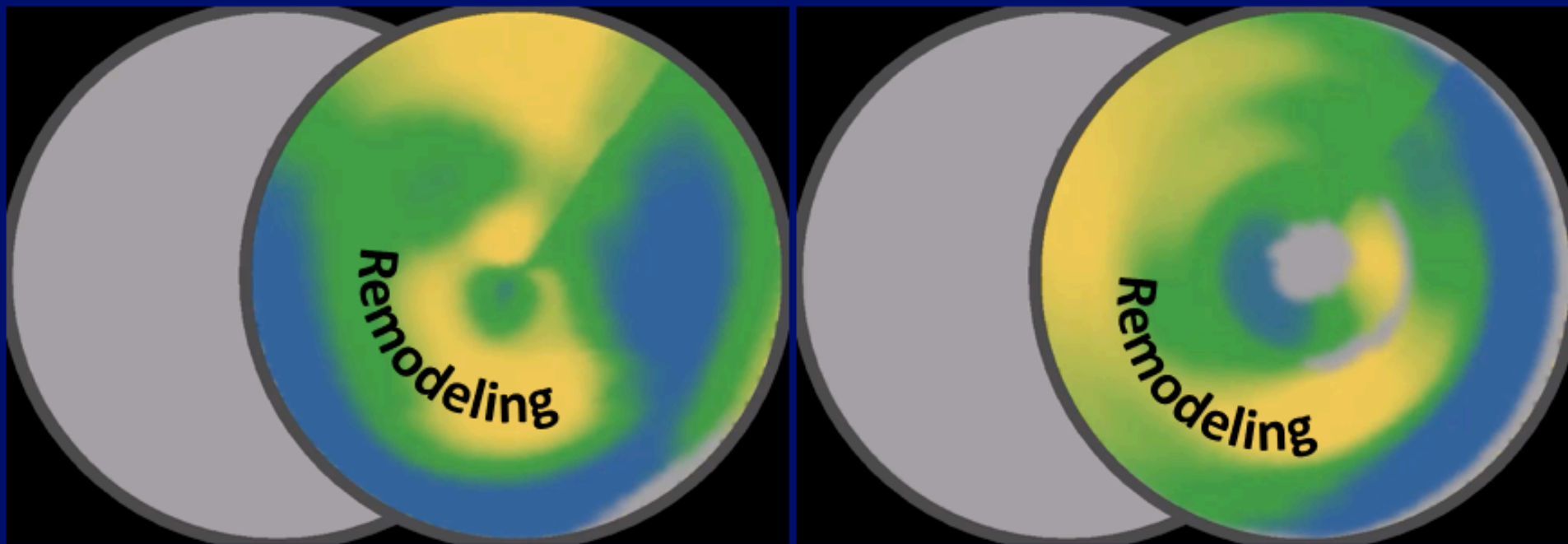
- Cardiac catheterization performed @ day 14
 - No stenosis in any coronary territory

9 | Hypertrophic Obstructive Cardiomyopathy

MYOSTRAIN IMAGING

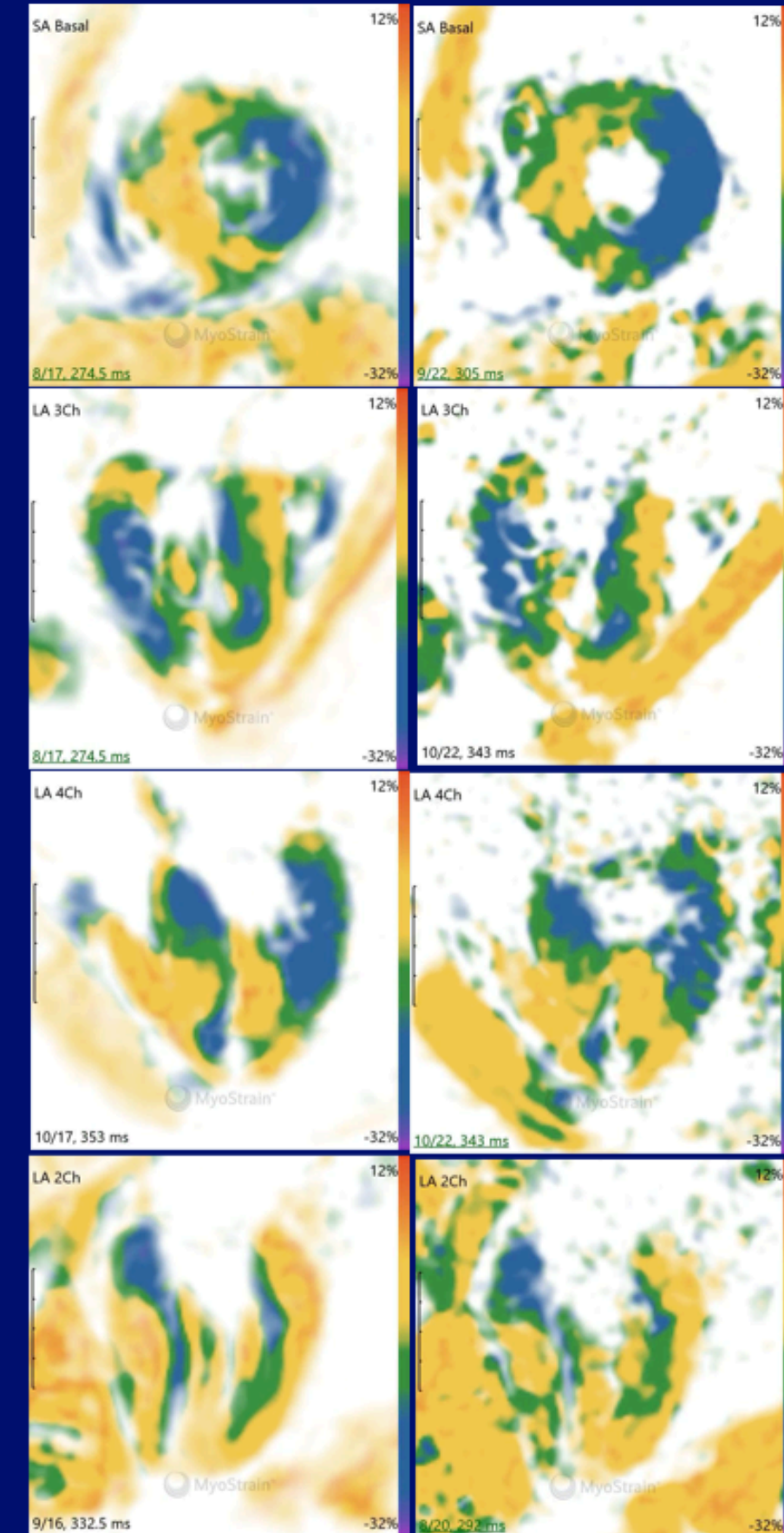
Circumferential

Longitudinal



Rest

Stress



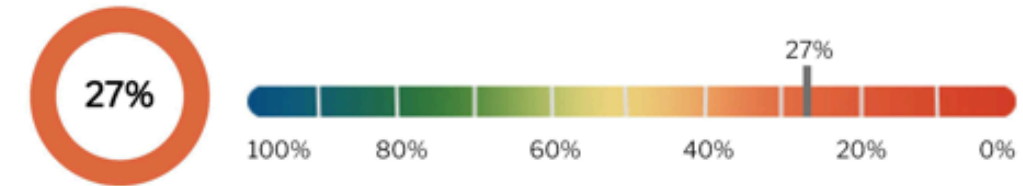
9 | Hypertrophic Obstructive Cardiomyopathy

MyoStrain® Results

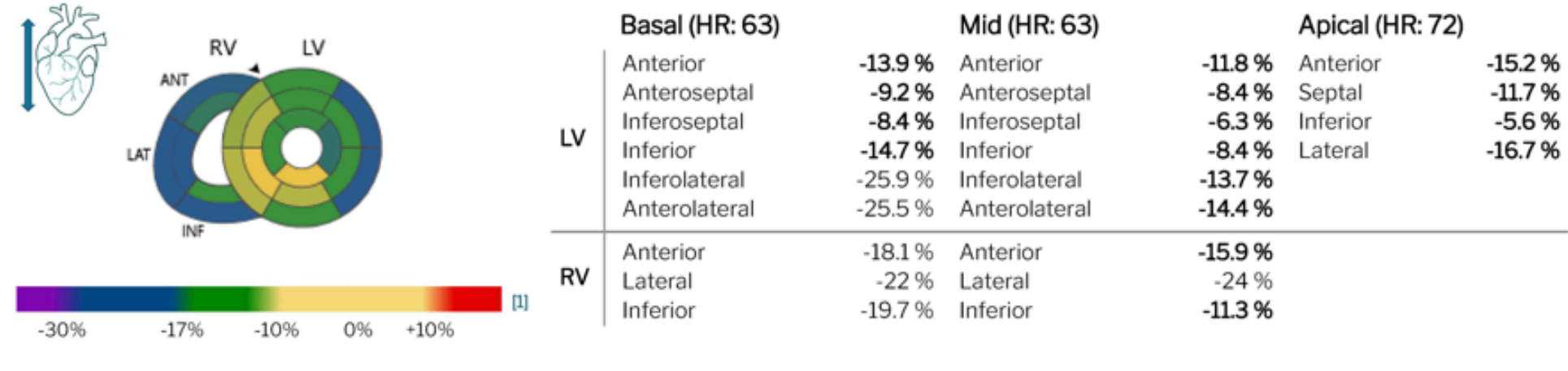
LV Dysfunctional Segments ^[1] (37/37 Segments Analyzed)

Number of Segments >-10% 10
Number of Segments >-17% 27

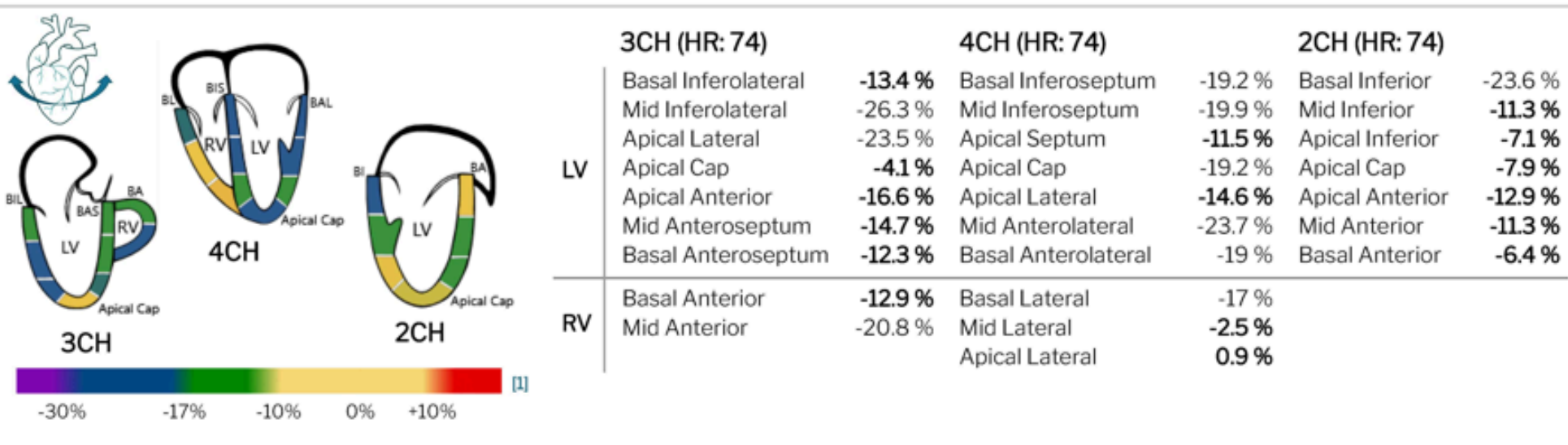
LV MyoHealth® (% Normal Segments ≤ -17%) ^[2]



Longitudinal MyoStrain® Measurements



Circumferential MyoStrain® Measurements



REPORT

10 | Hypertrophic Cardiomyopathy in Asymptomatic Athlete

Patient history

- 60-year Male
- History of HCM
- Athletic Lifestyle

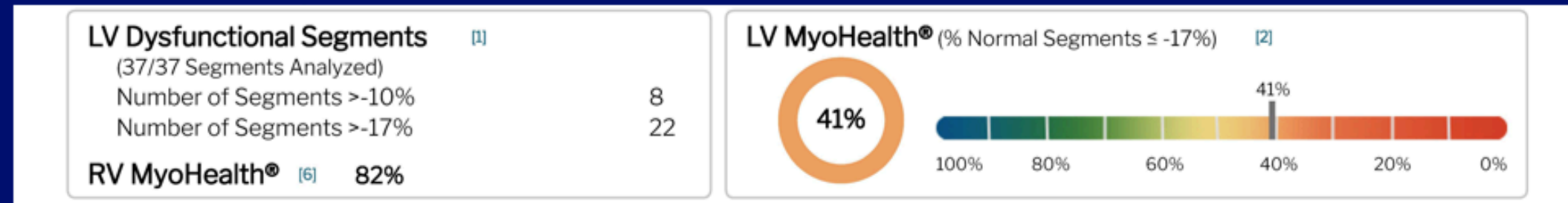
Clinical findings

MyoStress – December 29, 2020

- CMR LVEF – 74%
 - Septal Hypertrophy, Minimal Septal Scar (LGE)
- Abnormal MyoHealth (40%) with Dyssynchrony
 - 11 Segments > -10%
 - 22 Segments > -17%
- Ischemia potentially from microvascular obstruction (MVO)

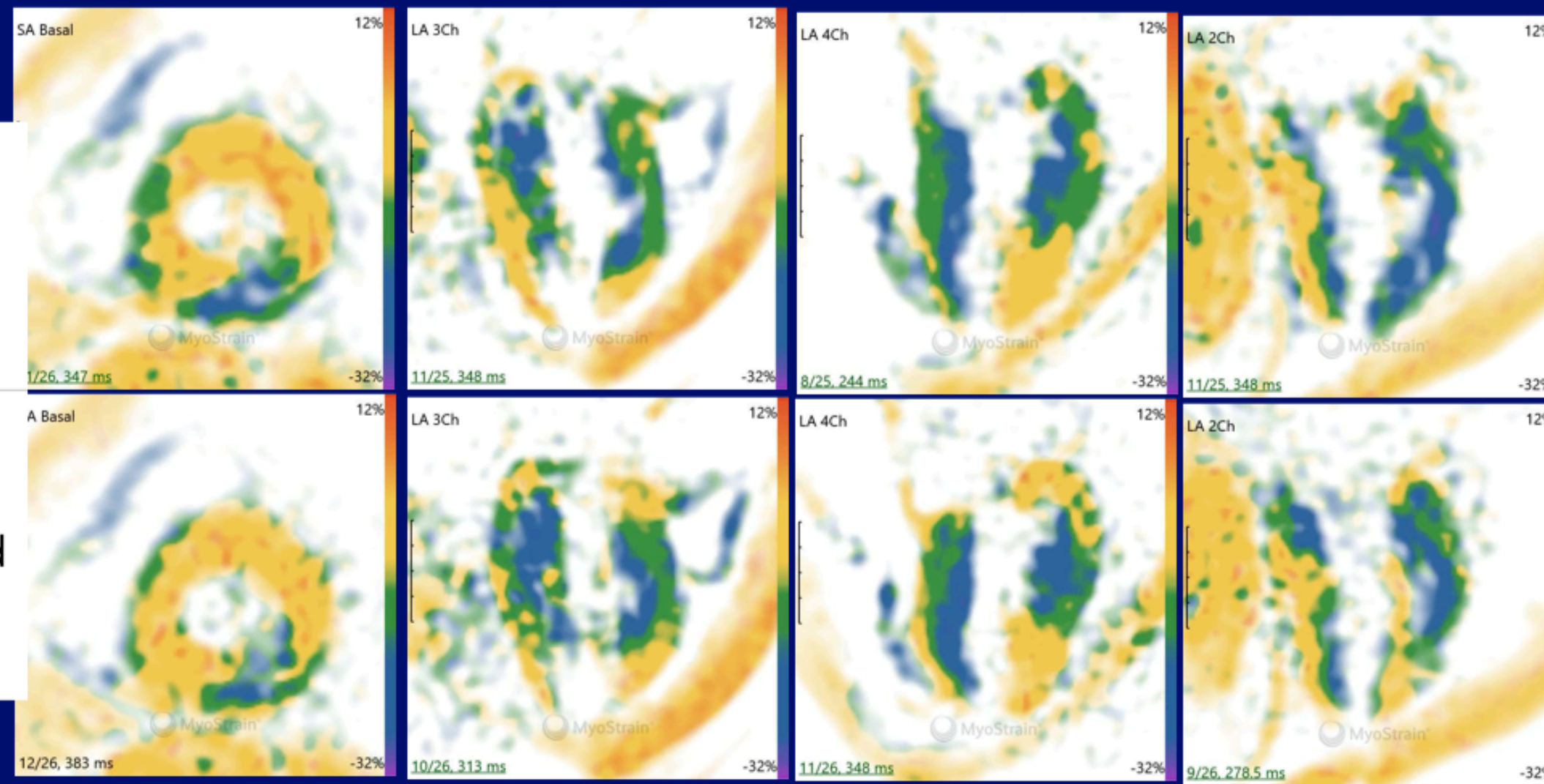
10 | Hypertrophic Cardiomyopathy in Asymptomatic Athlete

MYOSTRAIN IMAGING



Heart at Rest

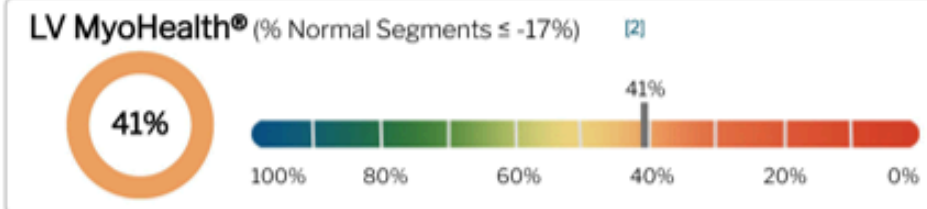
Stressed Heart



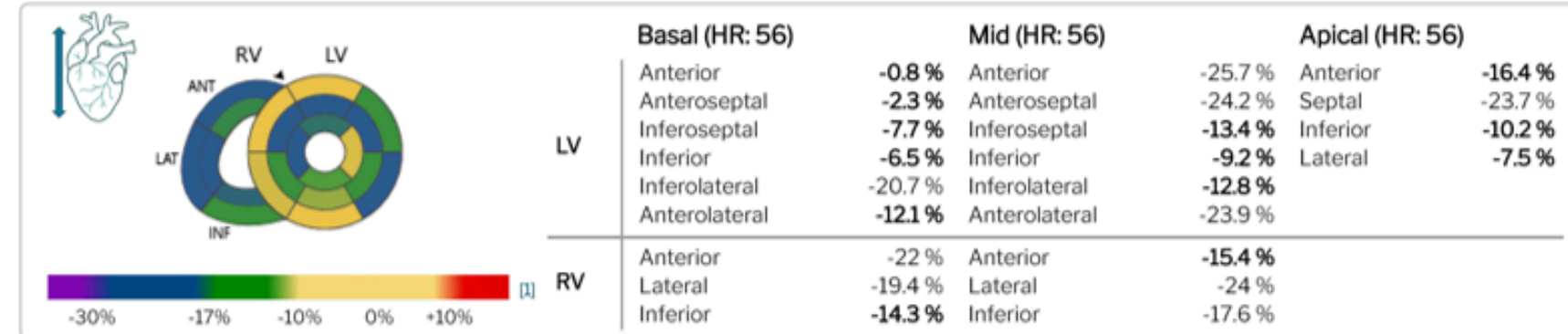
10 | Hypertrophic Cardiomyopathy in Asymptomatic Athlete

Heart at Rest MyoStrain® Results

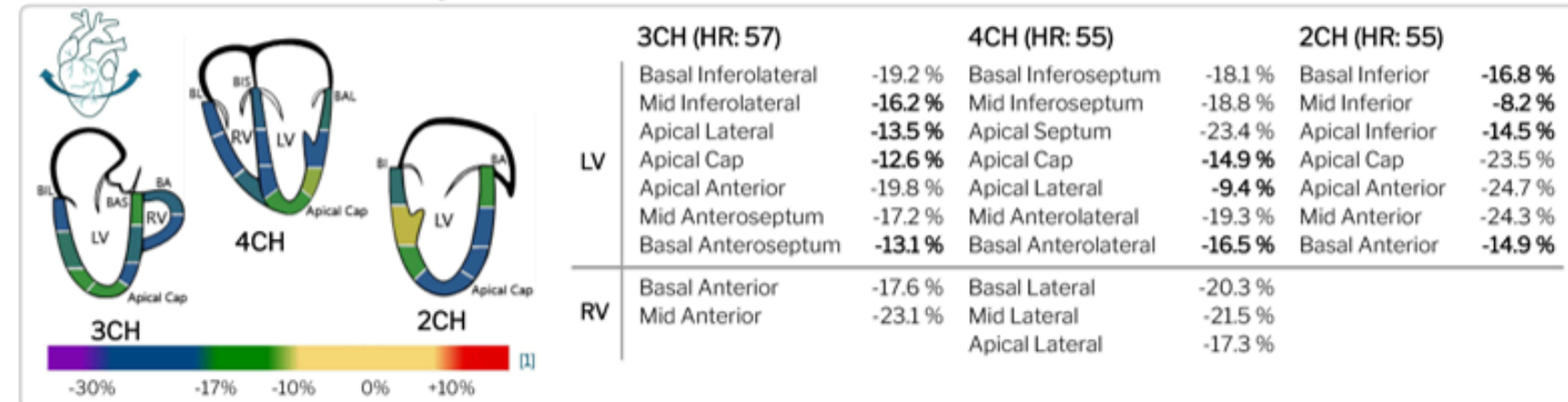
LV Dysfunctional Segments [1]
 (37/37 Segments Analyzed)
 Number of Segments >-10% 8
 Number of Segments >-17% 22
RV MyoHealth® [6] 82%



At Rest: Longitudinal MyoStrain® Measurements



At Rest: Circumferential MyoStrain® Measurements



At Rest: Global Results

Left Ventricle (LV)				Right Ventricle (RV)			
Global MyoStrain®	Result	Normal [1]		Global MyoStrain®	Result	Normal [1]	
MyoStrain (GLS) LV	-13.7 %	(<-17)		MyoStrain (GLS) RV	-18.8 %	(<-17)	
MyoStrain (GCS) LV	-17 %	(<-17)		MyoStrain (GCS) RV	-20 %	(<-17)	
LV Traditional Measurements	Result	Index	Normal [3]	RV Traditional Measurements	Result	Index	Normal [3]
LVEF	50.4 %	-	(53-74)	RVEF	65.6 %	-	(47-69)
LV Mass	177.6 g	84.98	(39-75) g/m2	RV ED Volume	143.1 ml	68.47	(57-108) ml/m2
LV ED Volume	183.7 ml	87.89	(53-99) ml/m2	RV ES Volume	49.3 ml	23.58	(20-49) ml/m2
LVES Volume	91.1 ml	43.58	(15-40) ml/m2	RV Stroke Volume	93.8 ml	44.88	(33-62) ml/m2
LV Stroke Volume	92.6 ml	44.31	(35-63) ml/m2				



REPORT

11 | MyoHealth[®] Monitors Amyloidosis Management

Patient history

- 55 yr Male
- Plasmacytoma (Lambda LK)
- AL Amyloidosis
- Amyloid Deposition in 50% of Cut Surfaces with Inflammation
- Amyloid Nephropathy
- Atrial Fibrillation
- Gastric Emptying Disorder

Clinical findings

Baseline CMR Exam

- Infarct-Atypical LGE diffuse, especially antero- & inferoseptal
- T1 diffuse spotty

Follow-Up #1 (day 82)

- Improved LVEF, volumes, mass

Follow-Up #2 (day 174)

- Unable to prescribe HF meds due to gastric emptying disorder
- Worsened LVEF, volumes, mass

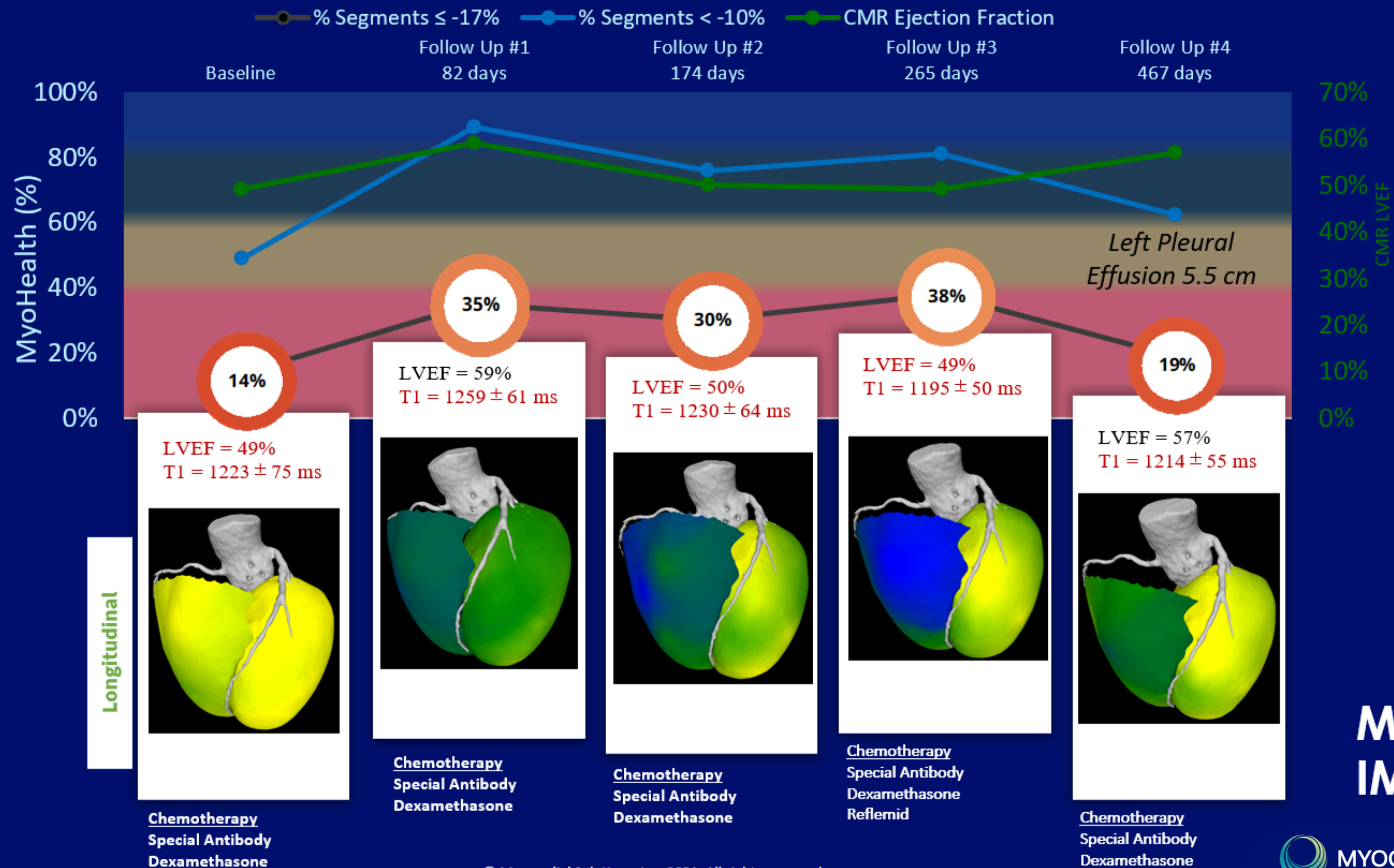
Follow-Up #3 (day 265)

- No Cardioprotective Medications
- Added Reflemid
- Stabilized LVEF, volumes, mass

Follow-Up #4 (day 467)

- No Cardioprotective Medications
- Stopped Reflemid & Imnovid due to side effects
- Despite stable LVEF, mass increased
- Left Pleural Effusion 5.5 cm

11 | MyoHealth[®] Monitors Amyloidosis Management



**MYOSTRAIN
IMAGING**

12 | Mitral Valve Disease (pre Mitra-Clip) with Preserved LVEF

Patient history

- 82-year female
- BMI – 25 kg/m²
- Diabetes Mellitus type 2
- Persistent Atrial Fibrillation
- Coronary Artery Disease (1-vessel)
- Prior Stroke
- Right hemiparesis
- Acute partial-fractionated infarction in anterior flow on left
- Decompensated HF 6/2019
- Mitral Valve Insufficiency II-III
- Tricuspid Valve Insufficiency II

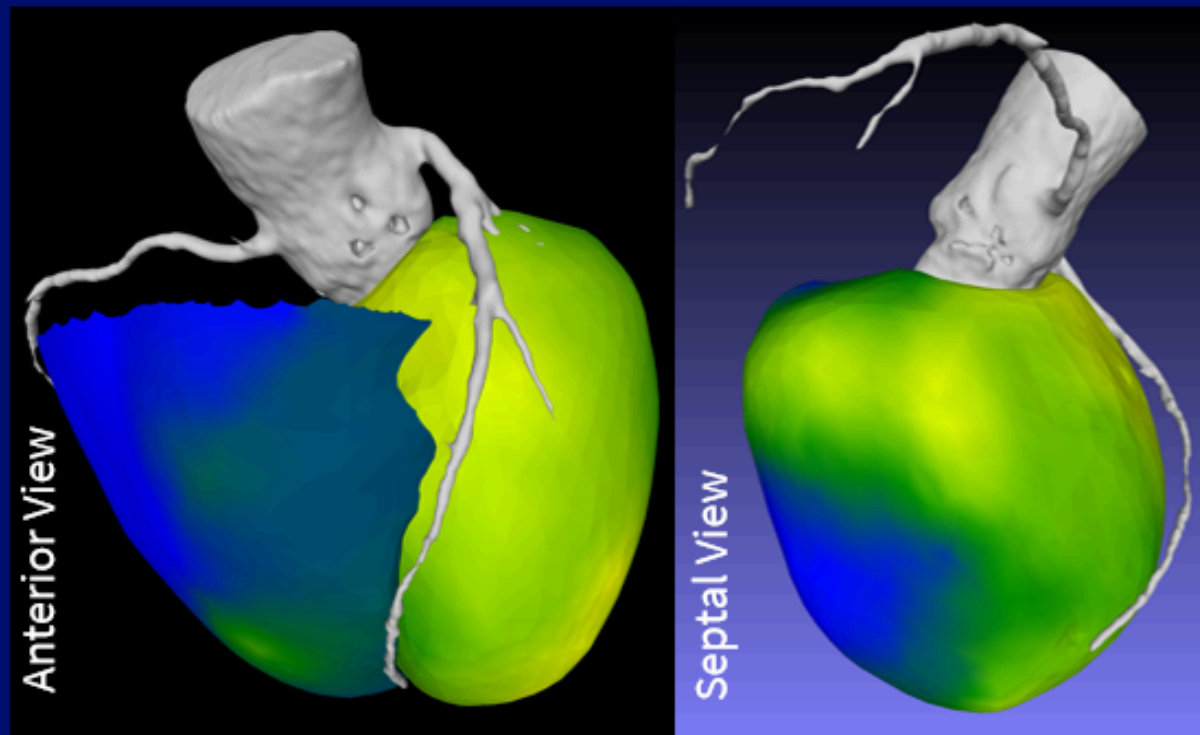
Clinical findings

CMR with MyoStrain

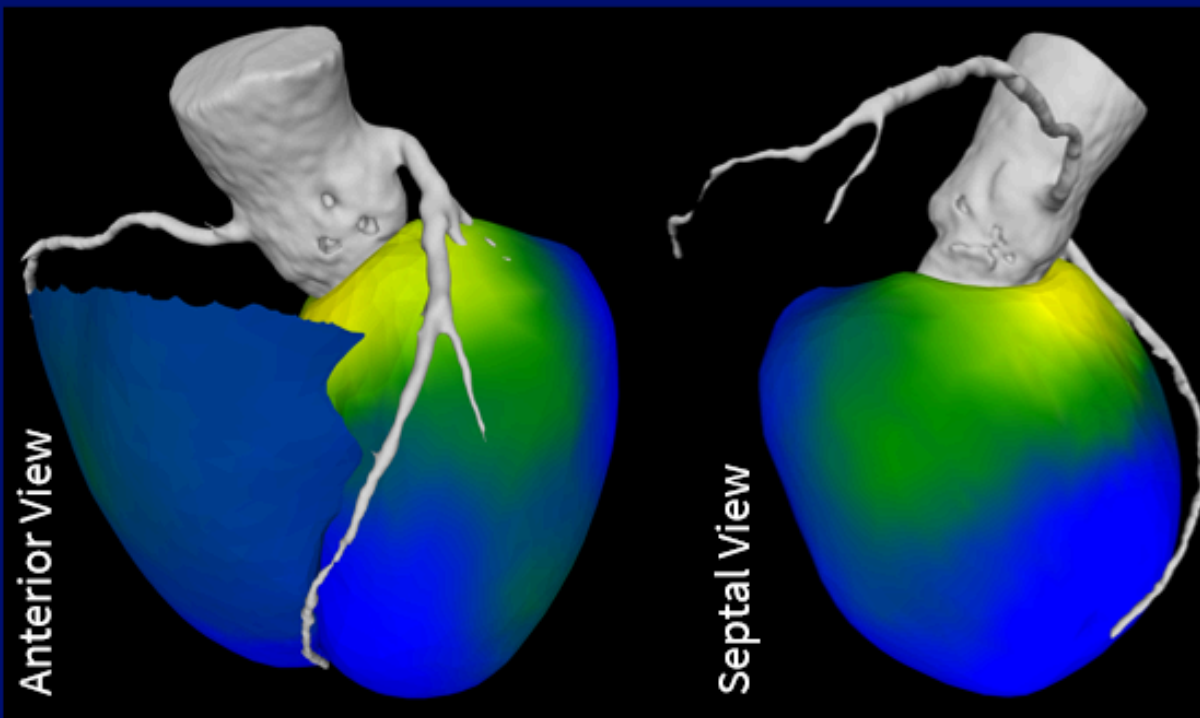
- No LGE
- % Normal MyoStrain – 46%
- % Functional MyoStrain – 78%
- MyoStrain Showed Dyssynchrony
- LVEF – 57%; MAPSE = 6 mm
- LVEDVI – 62 ml/m²; LVESVI – 26 ml/m²
- LV Stroke Volume Index – 36 ml/m²
- Septal WT – 9 mm; Lateral WT – 7 mm
- RVEF – 62%; TAPSE – 16 mm
- LVEDVI – 41 ml/m²; LVESVI – 15 ml/m²
- RV Stroke Volume Index – 26 ml/m²
- Ascending Aorta Diameter – 30 mm
- Left Atrial Diameter – 37 mm
- Descending aorta thrombus 35x10mm
- Thrombogenic aortic arch type

12 | Mitral Valve Disease (pre Mitra-Clip) with Preserved LVEF

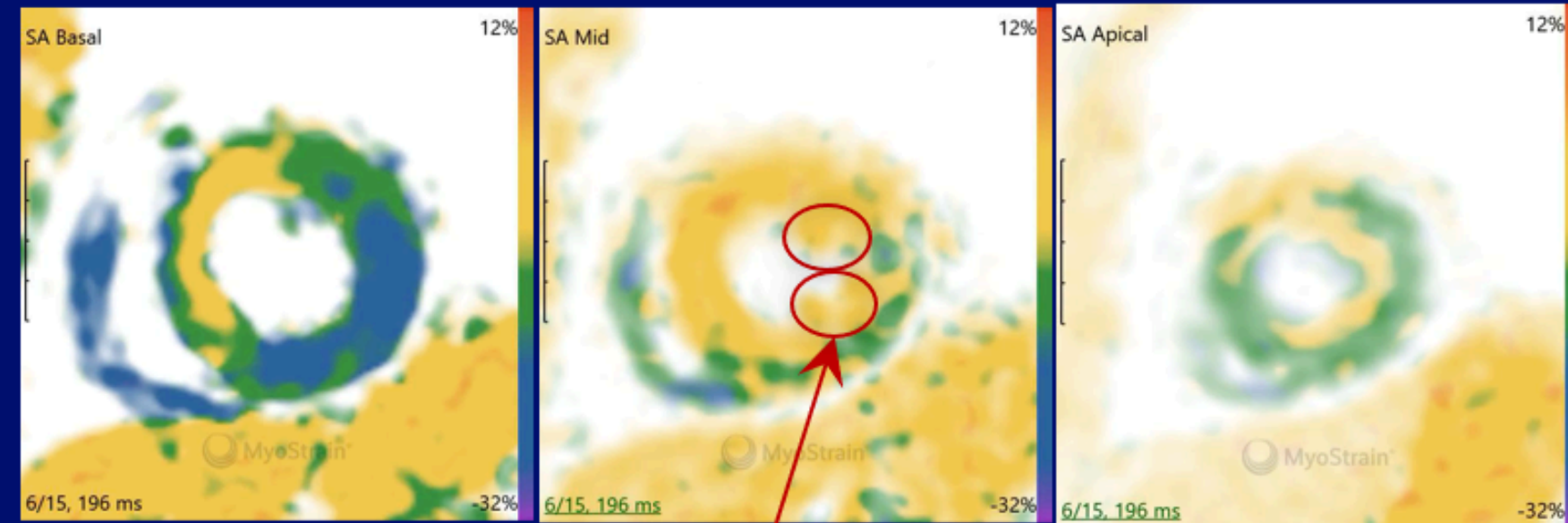
Longitudinal MyoStrain



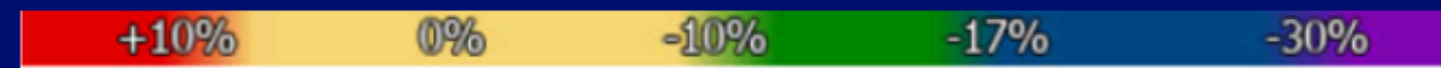
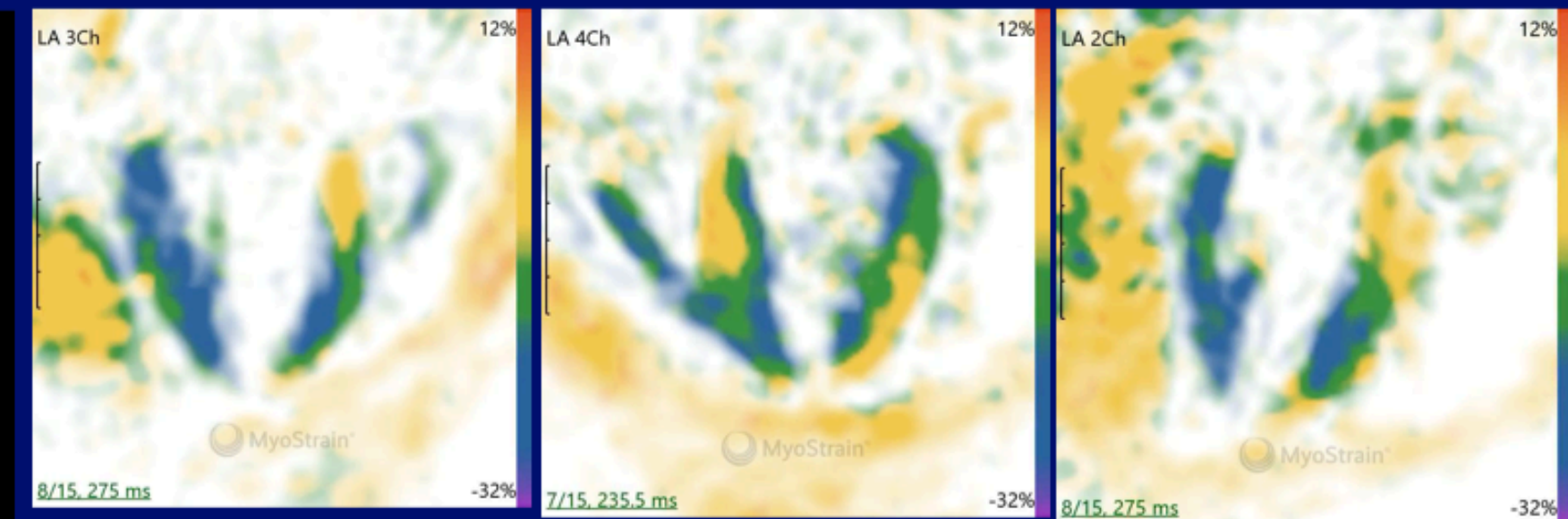
Circumferential MyoStrain



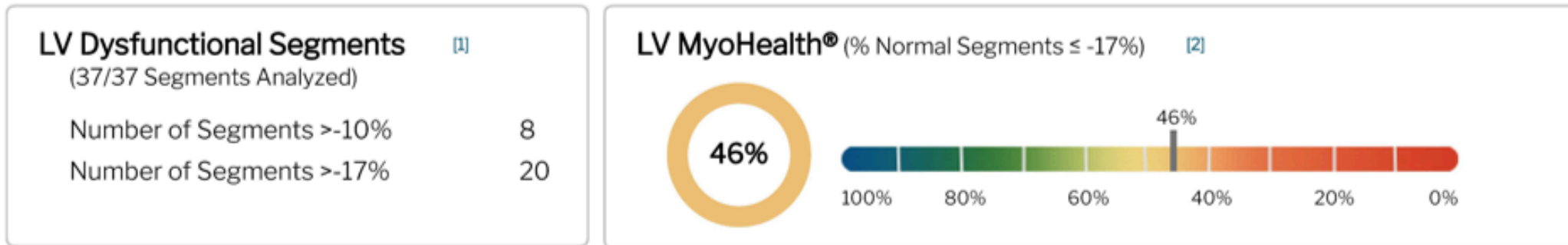
MYOSTRAIN IMAGING



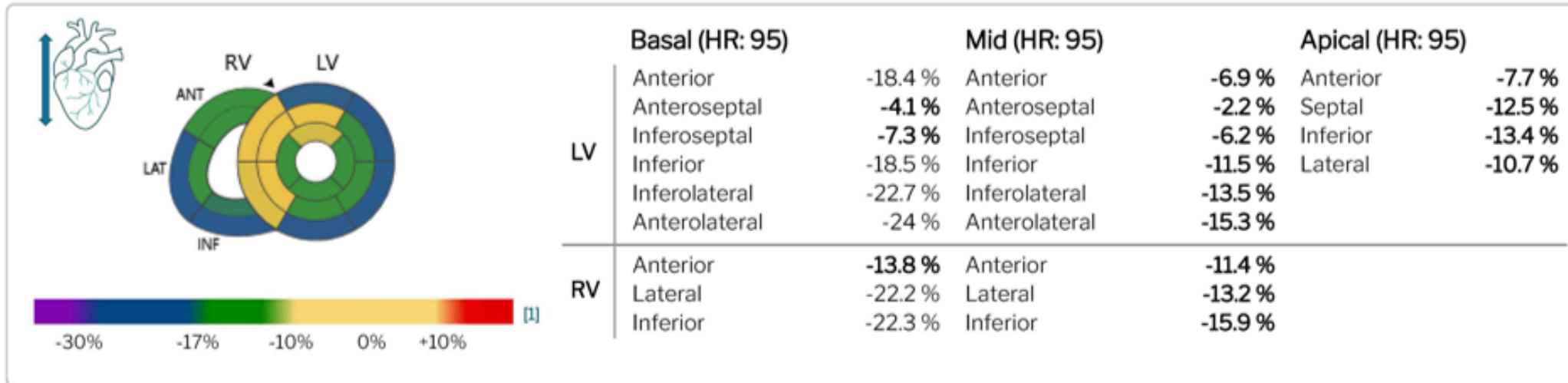
Poor Papillary Muscle Longitudinal Function



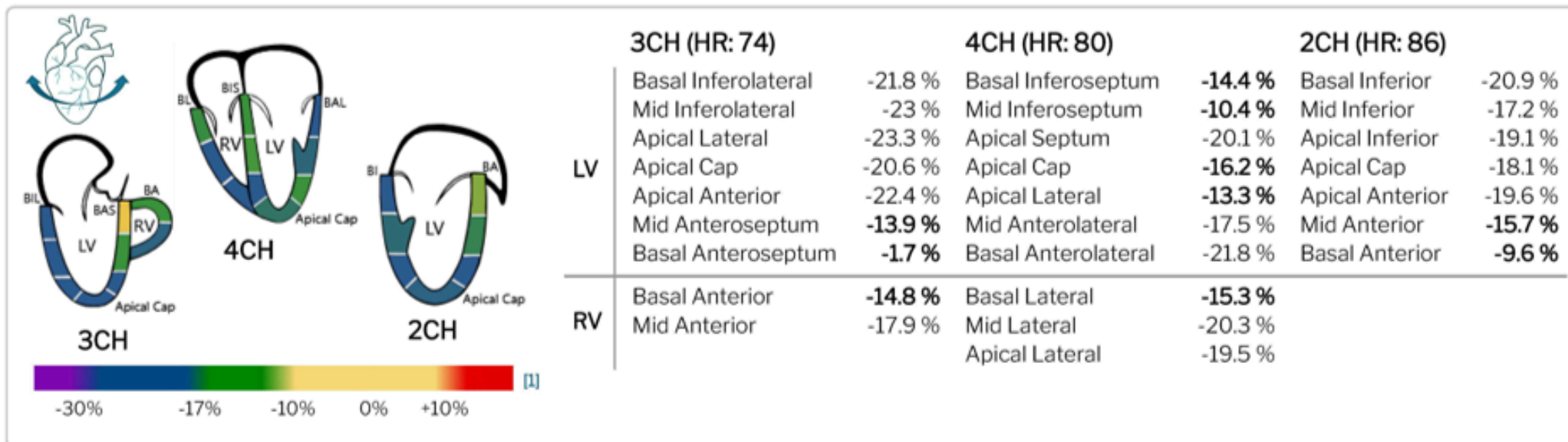
12 | Mitral Valve Disease (pre Mitra-Clip) with Preserved LVEF



Longitudinal MyoStrain® Measurements



Circumferential MyoStrain® Measurements



REPORT

13 | Tachymyopathy with Substantial Dyssynchrony

Patient history

- 65-year Female, Former Smoker (15 pys)
- Body Mass Index – 24 kg/m²
- Arterial Hypertension
- Hypercholesterolemia
- Ventricular Extra-Systoles

Clinical findings

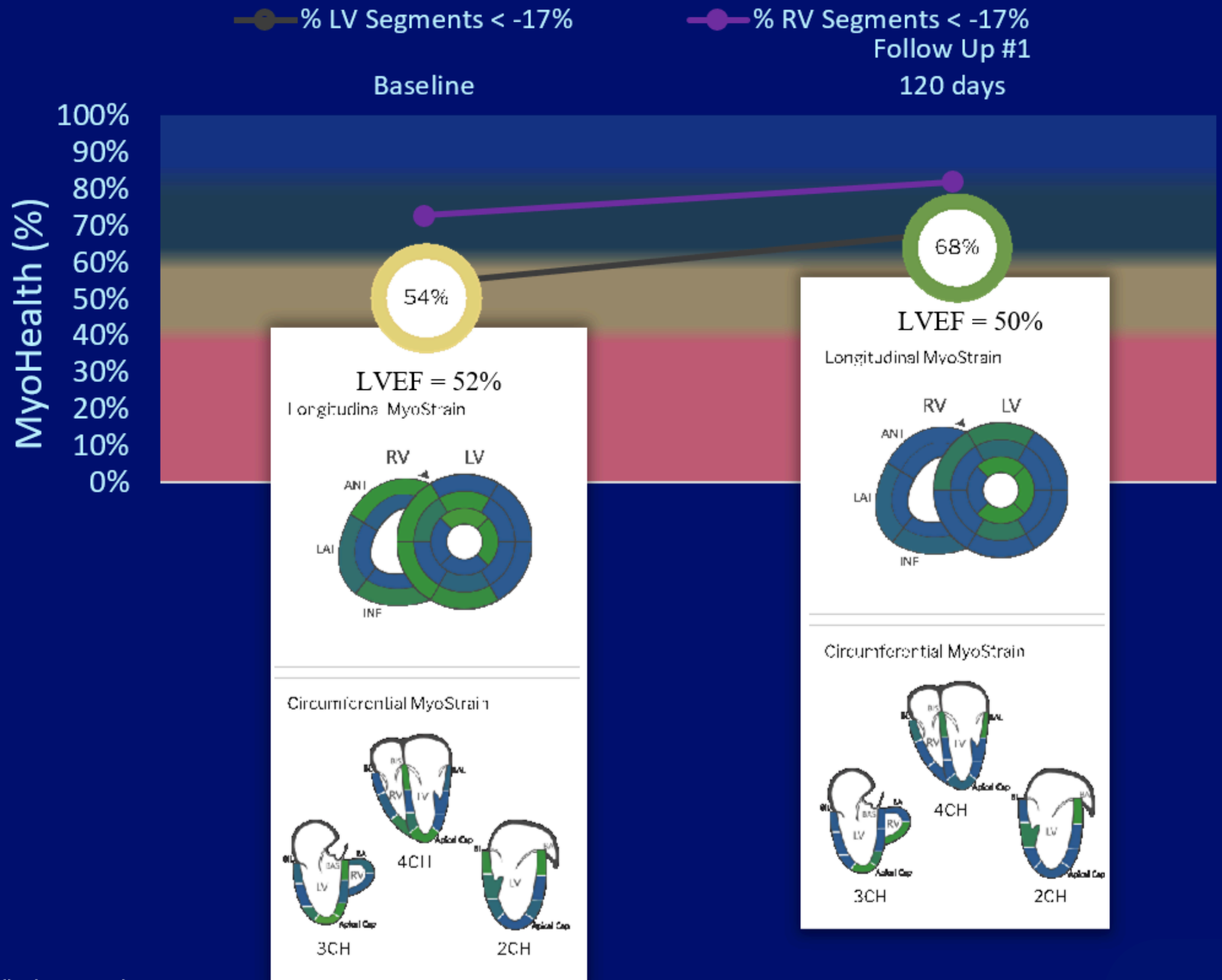
Baseline CMR – May 16, 2018

- NYHA I
- MyoHealth (54%) with Dyssynchrony; SI_MyoHealth – 40%
- LVEF – 52% RVEF – 55%
- LVEDVI – 87 ml/m²; LVESVI – 42 ml/m²
- MAPSE – 6 mm TAPSE – 26 mm
- Septal WT – 9 mm Lateral WT – 6 mm
- LA Diameter – 27 mm LA Area Index – 11 cm²/m²
- Ascending Aorta Diameter – 34 mm
- Moderate Mitral & Tricuspid Valve Regurgitation
 - Mitral Valve Prolapse
- Only Pericardial LGE (LGE Score – 0.9)

Follow-Up #1 – September 13, 2018 (120 days)

- NYHA I
- Atrial Fibrillation
- Improved MyoHealth (68%) with Dyssynchrony; SI_MyoHealth – 56%
- LVEF – 50% RVEF – 55%
- LVEDVI – 88 ml/m²; LVESVI – 39 ml/m²
- MAPSE – 6 mm TAPSE – 22 mm
- Septal WT – 9 mm Lateral WT – 7 mm
- LA Diameter – 29 mm LA Area Index – 12 cm²/m²
- Ascending Aorta Diameter – 34 mm
- Moderate Mitral & Tricuspid Valve Regurgitation
 - Mitral Valve Prolapse
- No Pericardial LGE (LGE Score – 0.9)

13 | Tachymyopathy with Substantial Dyssynchrony



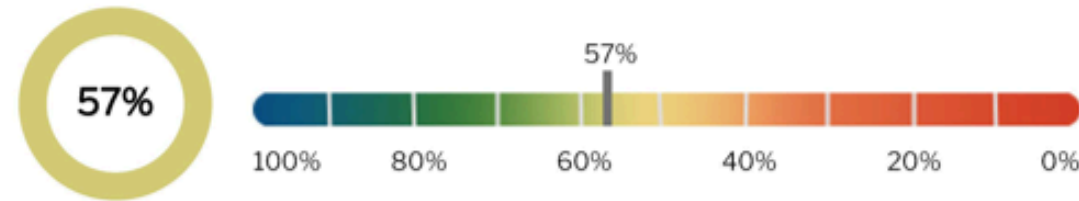
MYOSTRAIN IMAGING

13 | Tachymyopathy with Substantial Dyssynchrony

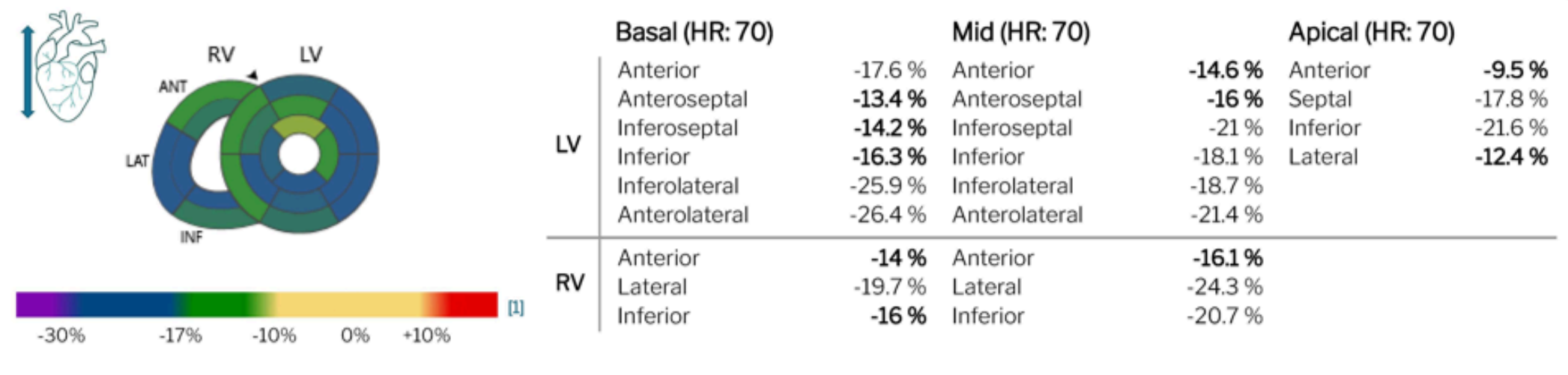
LV Dysfunctional Segments (37/37 Segments Analyzed)

Number of Segments >-10% **1**
 Number of Segments >-17% **16**

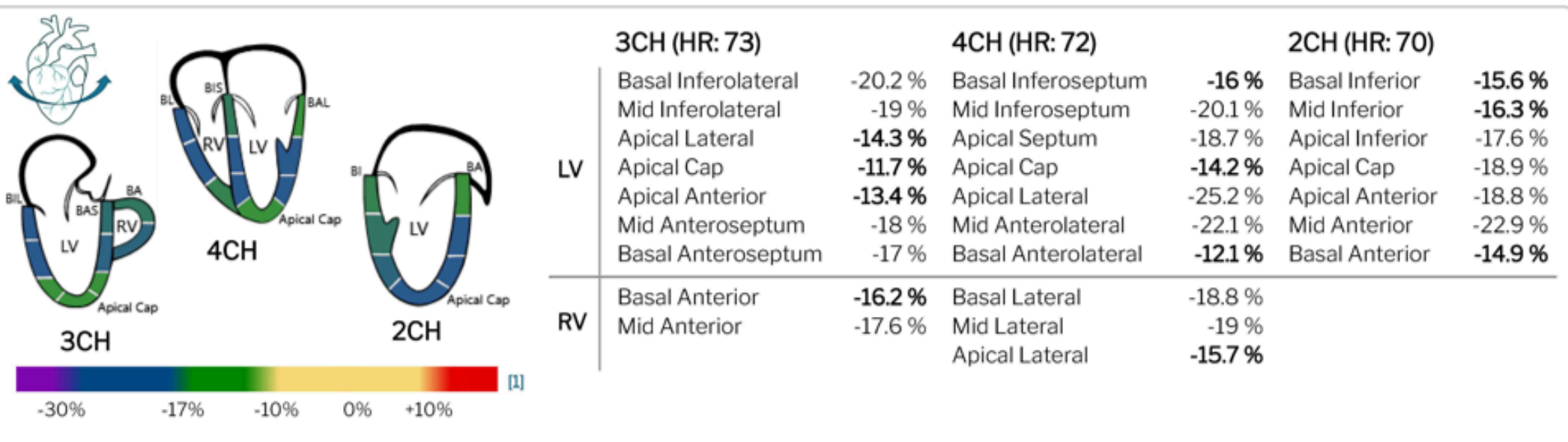
LV MyoHealth® (% Normal Segments ≤ -17%)



Longitudinal MyoStrain® Measurements



Circumferential MyoStrain® Measurements



REPORT

14 | Subclinical Cardiotoxicity with Reduced Stroke Volume Index

Patient history

- 40-year Female
- Body Mass Index – 30 kg/m²
- Highly malignant diffuse B-cell Non-Hodgkin's lymphoma (parotid tumor)

Clinical findings

Baseline (day 0)

- Normal MyoHealth – 84%
- Normal CMR LVEF (62%)
- Normal Biomarkers

Follow-up #1 (day 43)

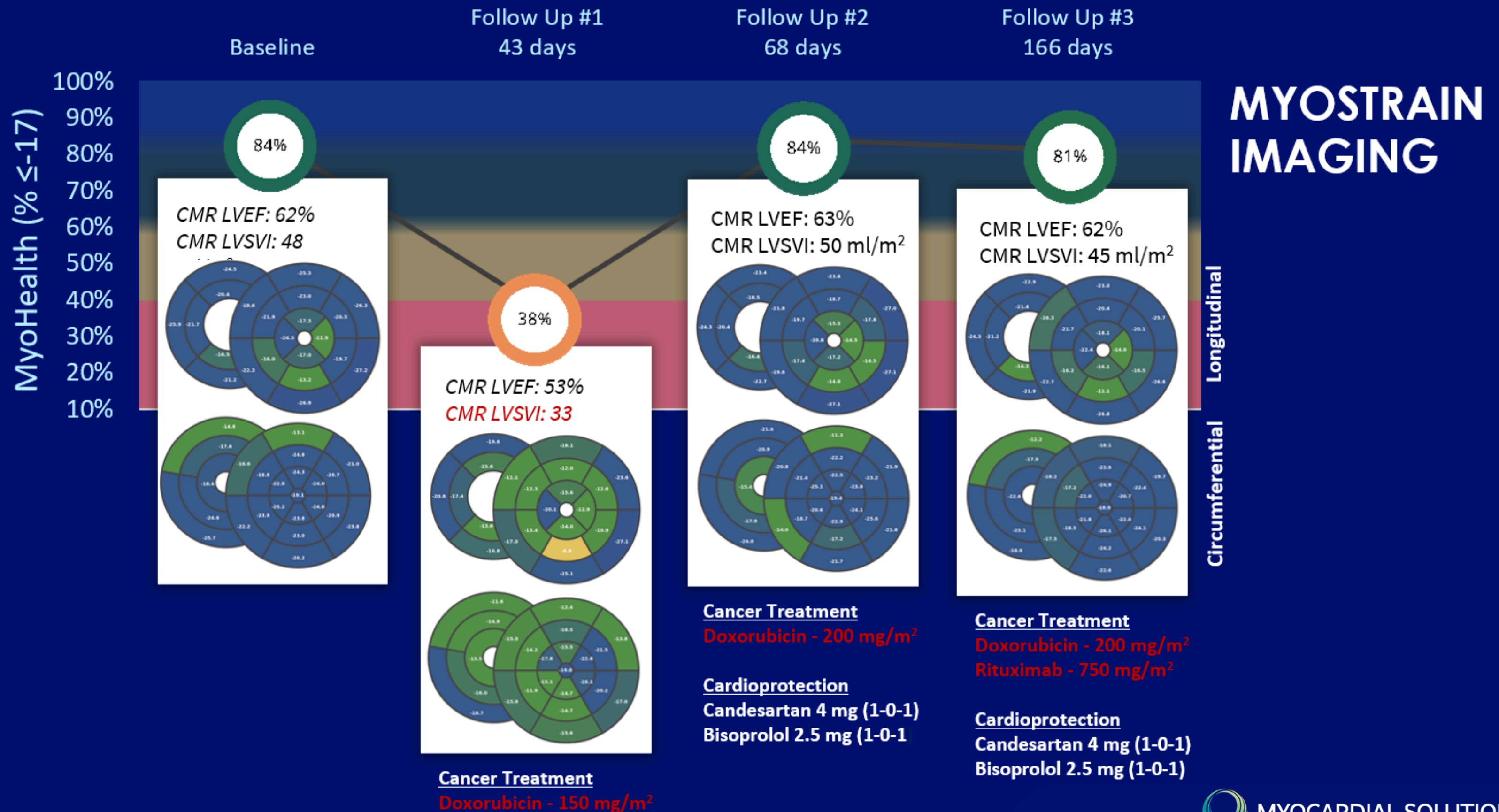
- Abnormal MyoHealth – 38%
- Normal CMR LVEF (53%)
- Abnormal Stroke Volume Index – 33 ml/m²
- Reduced MAPSE (9 mm)
- Normal Biomarkers

Follow-up #2 (day 68) – Cardioprotective Tx

- Normal MyoHealth – 84%
- Normal LVEF & Stroke Volume Index
- Normal Biomarkers

Late F/U (day 397) – No Adverse Events; Cardioprotective medications discontinued

14 | Subclinical Cardiotoxicity with Reduced Stroke Volume Index



15 | Subclinical Cardiotoxicity with Reduced Stroke Volume Index

Patient history

- 50-year Female, Smoker (5 yrs)
- Body Mass Index – 23 kg/m²
- Breast cancer
- Arterial hypertension
- Hypercholesterolemia
- Charlson comorbidity index: 1
- Mayo cardiotoxicity risk score: 5

Clinical findings

Baseline – 2/19/2019

- Normal MyoHealth – 89% (Slight Dyssynchrony)
- Normal CMR LVEF (72%) & RVEF (70%)
 - LVEDVI – 64 ml/m²; LVESVI – 18 ml/m²
- Normal Echo LVEF (68%)

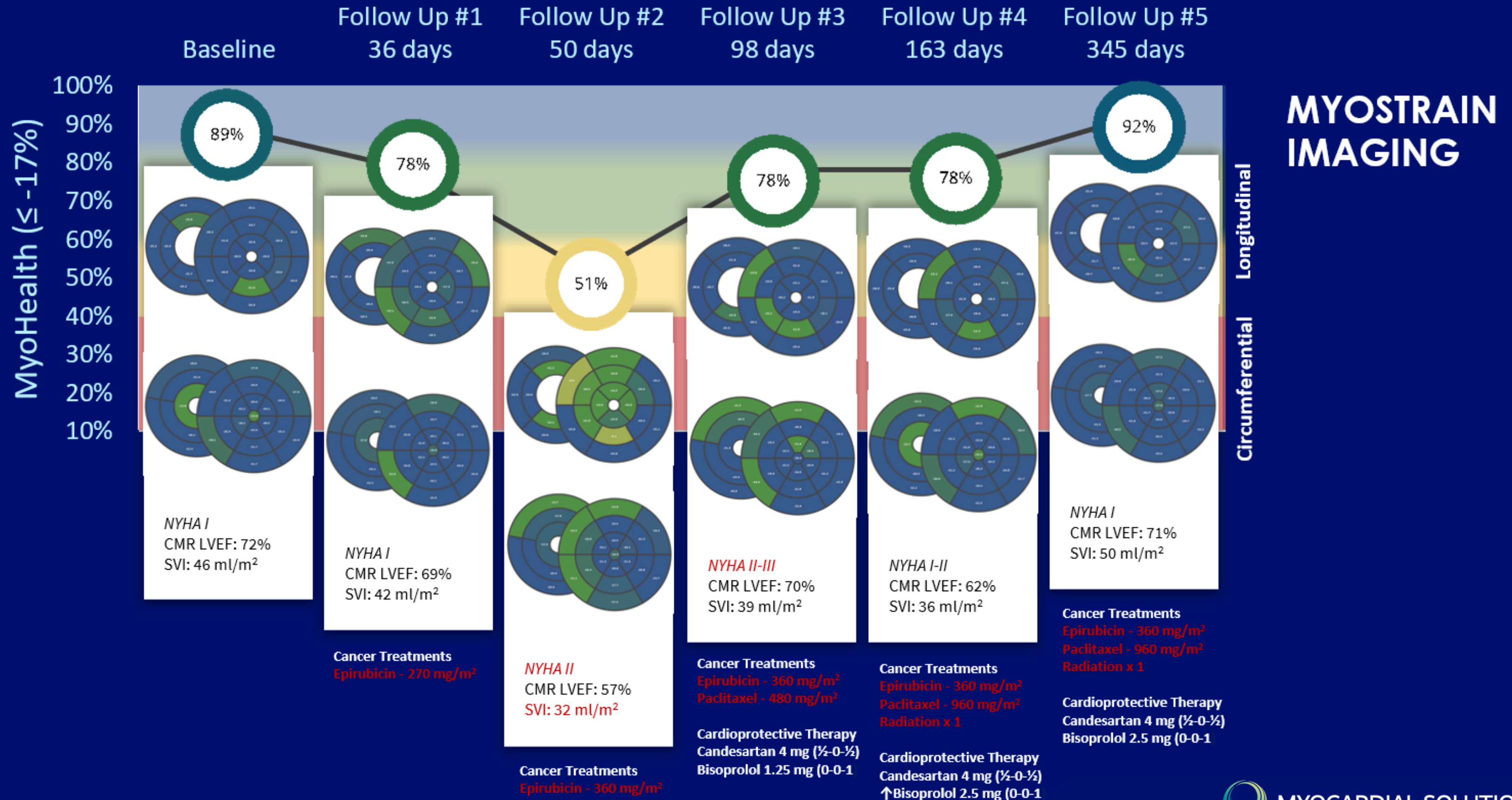
Follow-up #2 – 4/10/2019 (50 days)

- Abnormal MyoHealth – 51% (↑ Dyssynchrony)
- Normal CMR LVEF (57%) & RVEF (62%)
 - LVEDVI – 55 ml/m²; LVESVI – 23 ml/m²
- Abnormal Stroke Volume Index – 32 ml/m²
- Abnormal MAPSE (6 mm)
- Normal Echo LVEF (59%)

Follow-up #4 – 1/30/2020 (345 days) - Cardioprotection

- Normal MyoHealth – 92% (↓ Dyssynchrony)
- Normal LVEF, RVEF, MAPSE, & Stroke Volume
 - LVEDVI – 58 ml/m²; LVESVI – 22 ml/m²
 - **Late F/U (486 days)** – New Dyspnea under Exertion at 36 days (F/U #1) & New Decrease in Physical Exertion at 50 days (F/U #2); Cardioprotection prescribed after 50 day (F/U #2)

15 | Subclinical Cardiotoxicity with Reduced Stroke Volume Index



16 | Prior Transmural Posterior RCA Infarct without Ischemia

Patient history

- 77-year female, non-smoker
- BMI: 24 kg/m²; BSA: 1.69 m²
- Arterial Hypertension – Hypertensive Heart Disease
- Septal WT – 9 mm; Lateral WT – 4 mm
- Hypercholesterolemia
- Borderline Diabetes Mellitus
- Known Coronary Artery Disease
- Prior STEMI – posterior wall in acute RCA occlusion
- Recannalization / PCI / Stent 8/29/17
- LAD & LCX stenoses
- Moderate mitral valve regurgitation

Clinical findings

Perfusion CMR with MyoStress (Adenosine)

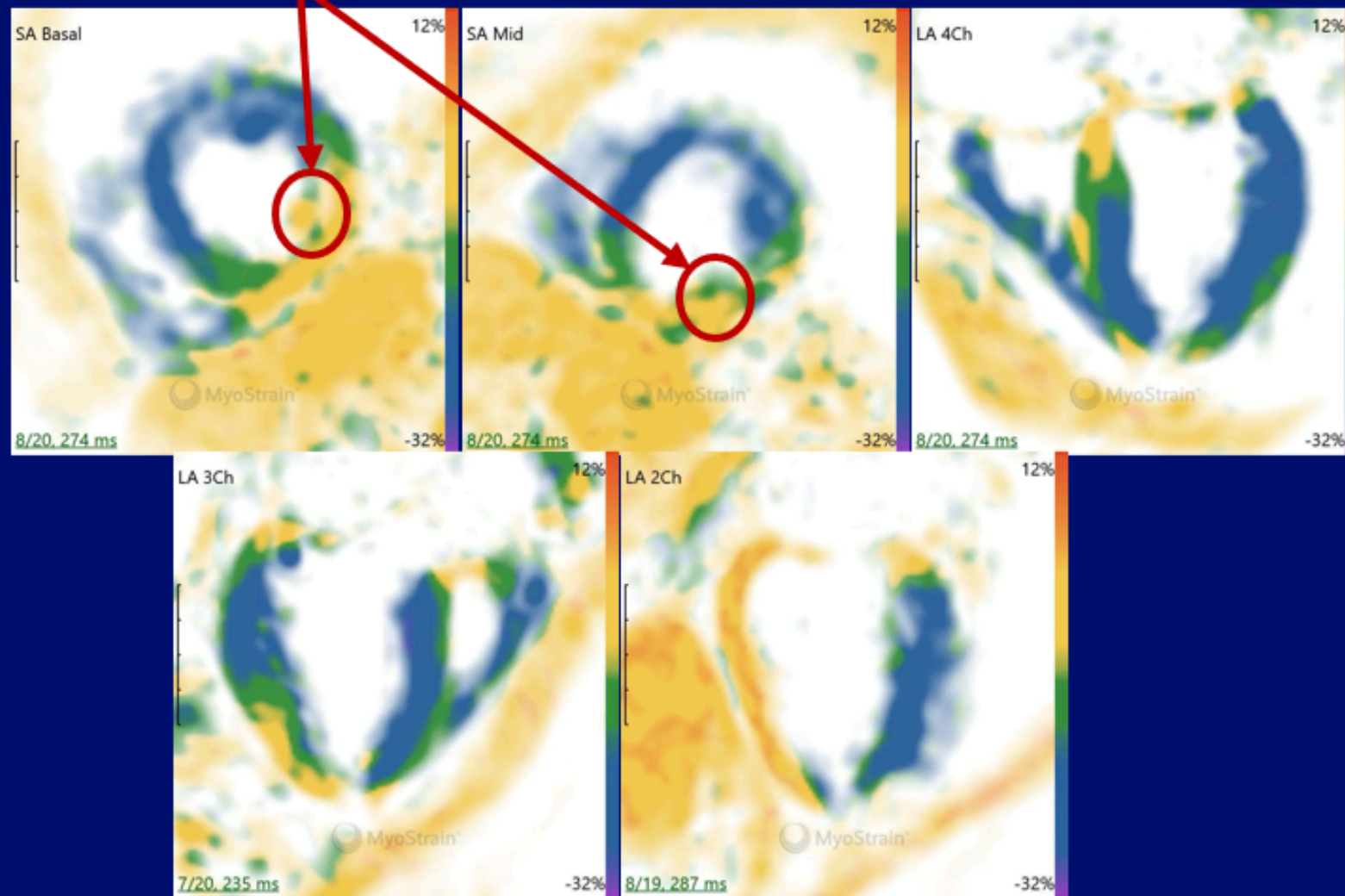
- NYHA II-III
- Abnormal MyoHealth – 57%; Slight Dyssynchrony
 - LVGLS –16.4; LVGCS -16.9
 - 0 ischemic segments (rest – stress \leq -6.5)
- LVEF – 46%; LVSVI – 44 ml/m²
 - LVEDVI – 98 ml/m²; LVESVI – 54 ml/m²
- Mass Index – 53 g/m²
- MAPSE – 11 mm
- RVEF – 59%; RVSVI – 44 ml/m²
 - RVEDVI – 75 ml/m²; RVESVI – 31 ml/m²
- Left Atrial Diameter – 44 mm; LA Area – 16 cm²/m²
- Hypo-Akinesia – BIS/BI/MI/MIL – WMA score 1.47
- LGE score (aLGE x tLGE x Septal WT) – 1.75
 - Infarct-typical LGE BIS/BI/MI/MIL (>75%):
 - tLGE score – 1.94
 - No infarct-atypical LGE: aLGE score – 1.00
- No Perfusion defects detected: PD score – 1.00
- **Microperfusion disorder detected – “small vessel disease”**

Post-Imaging Follow-Up (985 days)

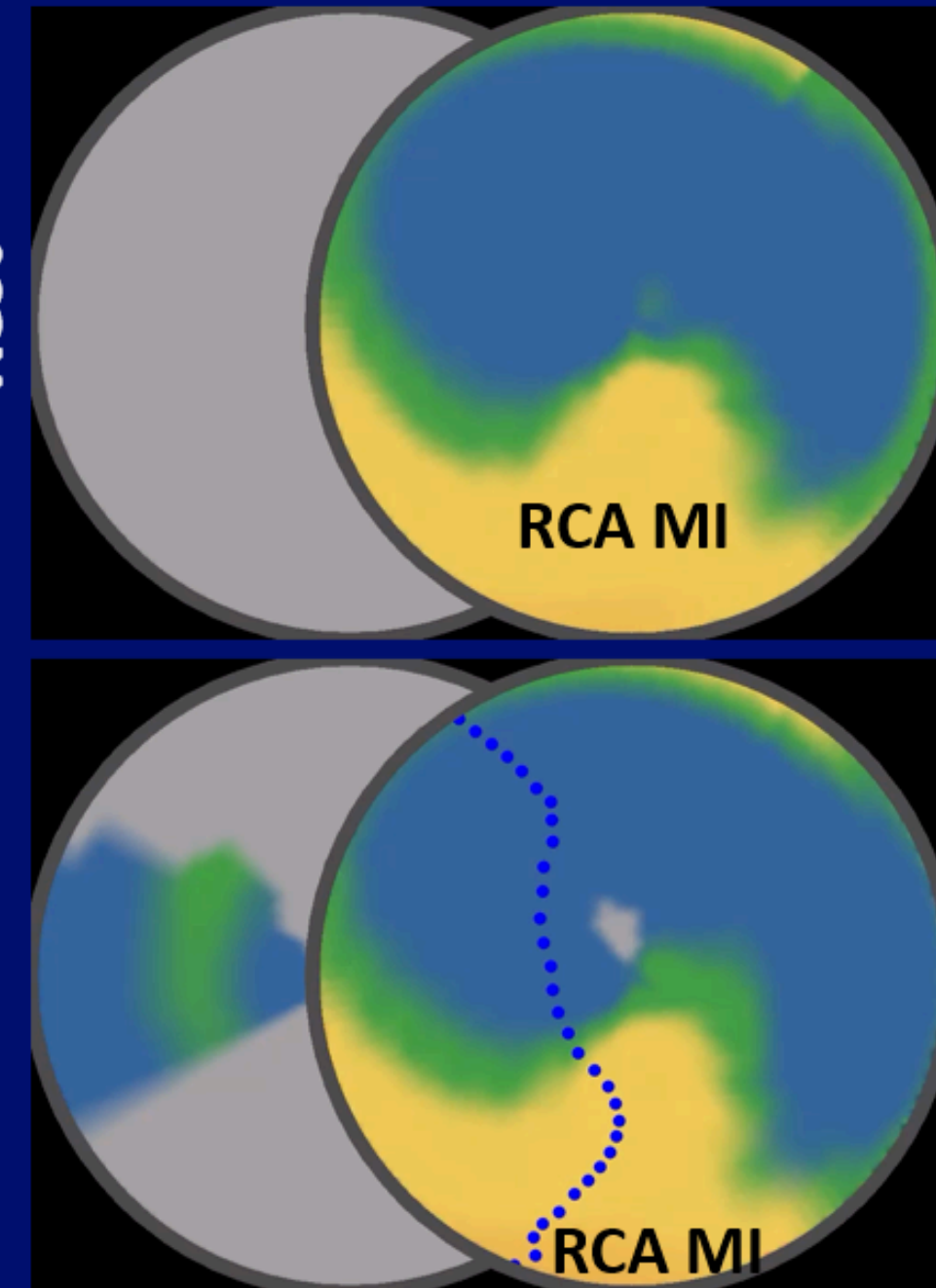
- No adverse events observed
- Cardio-active medications: statin & beta-blocker

16 | Prior Transmural Posterior RCA Infarct without Ischemia

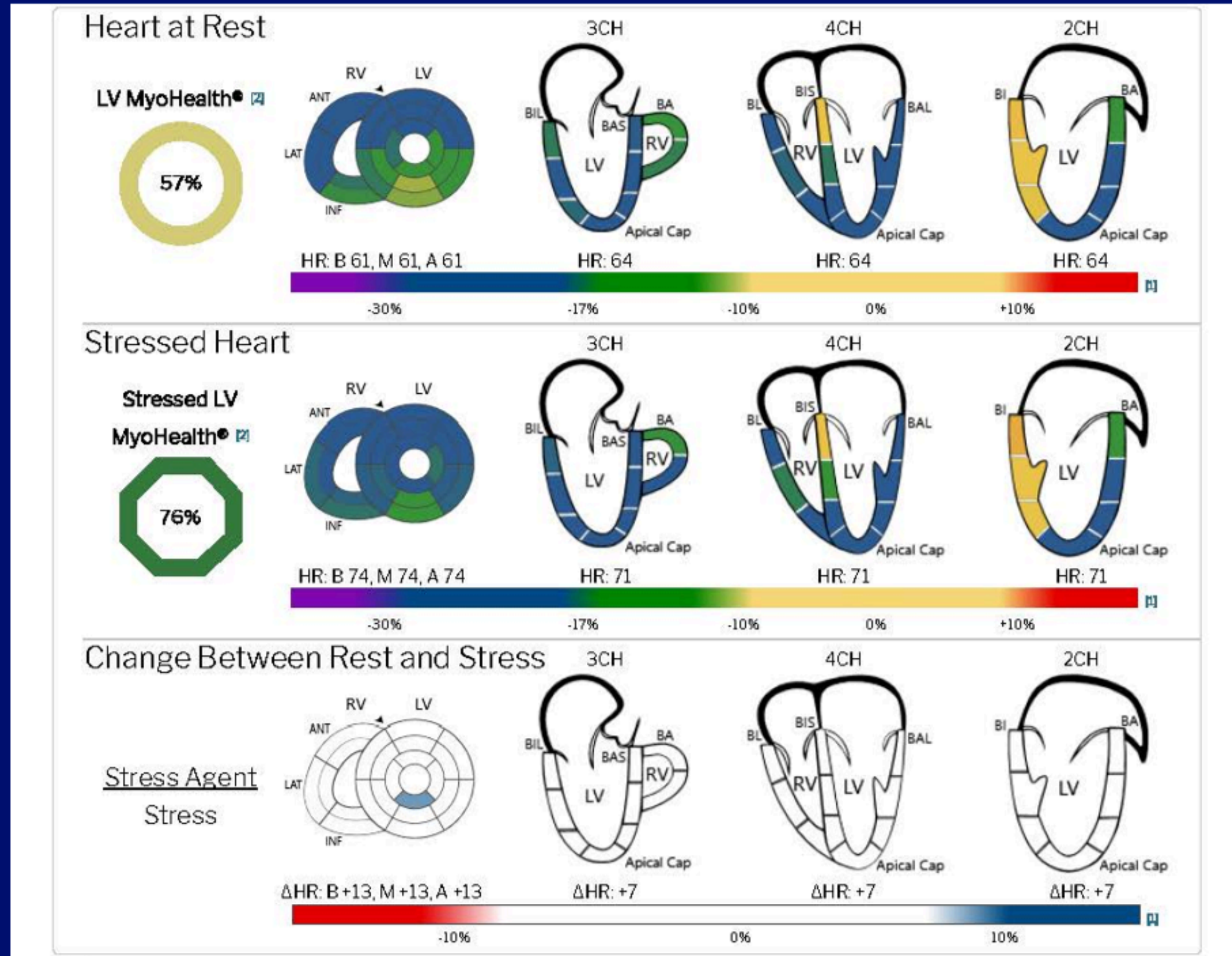
Poor Inferior Papillary
Muscle Function – RCA
Infarct



Circumferential
Rest
Stress



16 | Prior Transmural Posterior RCA Infarct without Ischemia



REPORT

17 | Ischemic Coronary Artery Disease with 90% LAD & 90% RCA Stenoses

Patient history

- 64 year male, non-smoker
- BMI: 23 kg/m²; BSA: 1.93 m²
- Arterial Hypertension – Mild Hypertensive Heart Disease
- LV hypertrophy (Septal WT – 11 mm; Lateral WT – 5 mm)
- Diastolic dysfunction
- Left atrial dilation – 36 mm (LA Area Index: 14 cm²/m²)
- Mild ectasia of ascending aorta – 34 mm
- Hypercholesterolemia
- Known CAD with PCI/DES of LCX 2011/2013 & LAD/D1 2013
- Moderate mitral & tricuspid valve regurgitation

Clinical findings

Perfusion CMR with MyoStress (Adenosine)

- NYHA II
- MyoHealth – 57%
 - 2 ischemic segments (rest – stress \leq -6.5)
 - Substantial dyssynchrony that worsened during stress
- LVEF – 60%; MAPSE – 12 mm; Mass Index – 59 g/m²
 - LVEDVI – 88 ml/m²; LVESVI – 35 ml/m²; LVSVI – 53 ml/m²
- RVEF – 63%; TAPSE – 19 mm
 - RVEDVI – 87 ml/m²; RVESVI – 36 ml/m²; RVSVI – 51 ml/m²
- Infarct-typical LGE: tLGE score – 1.18
 - Mid anterolateral / inferolateral / inferoseptal (25%)
- Perfusion defects of LAD / D1 & potentially LCX: PD score – 1.94
 - Basal anterior / anteroseptal / inferoseptal (25-75%)
 - Mid anteroseptal / anterior / anterolateral (25-75%)
 - Apical anterior / septal (25-75%)

Post-Imaging Follow-Up

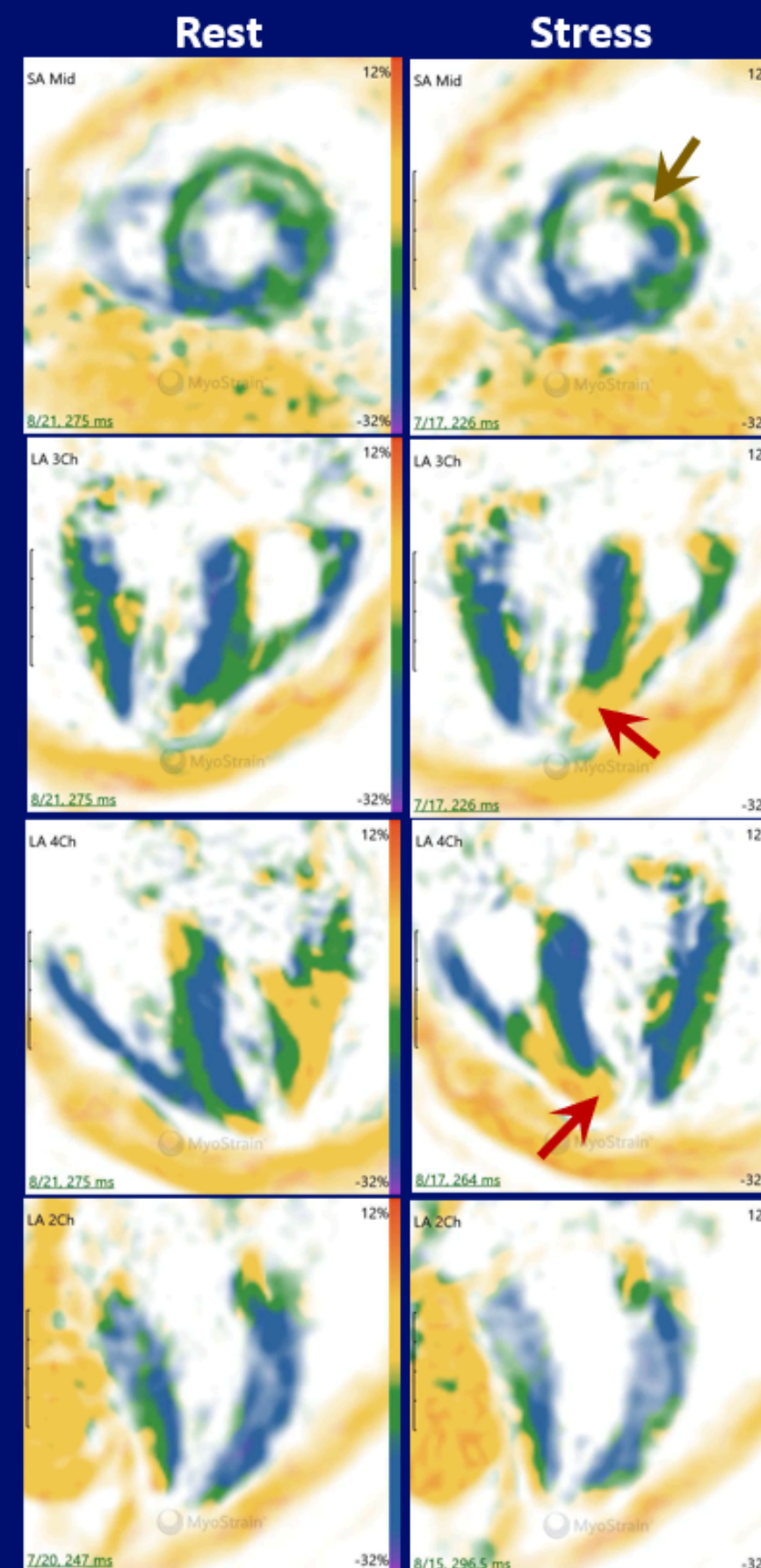
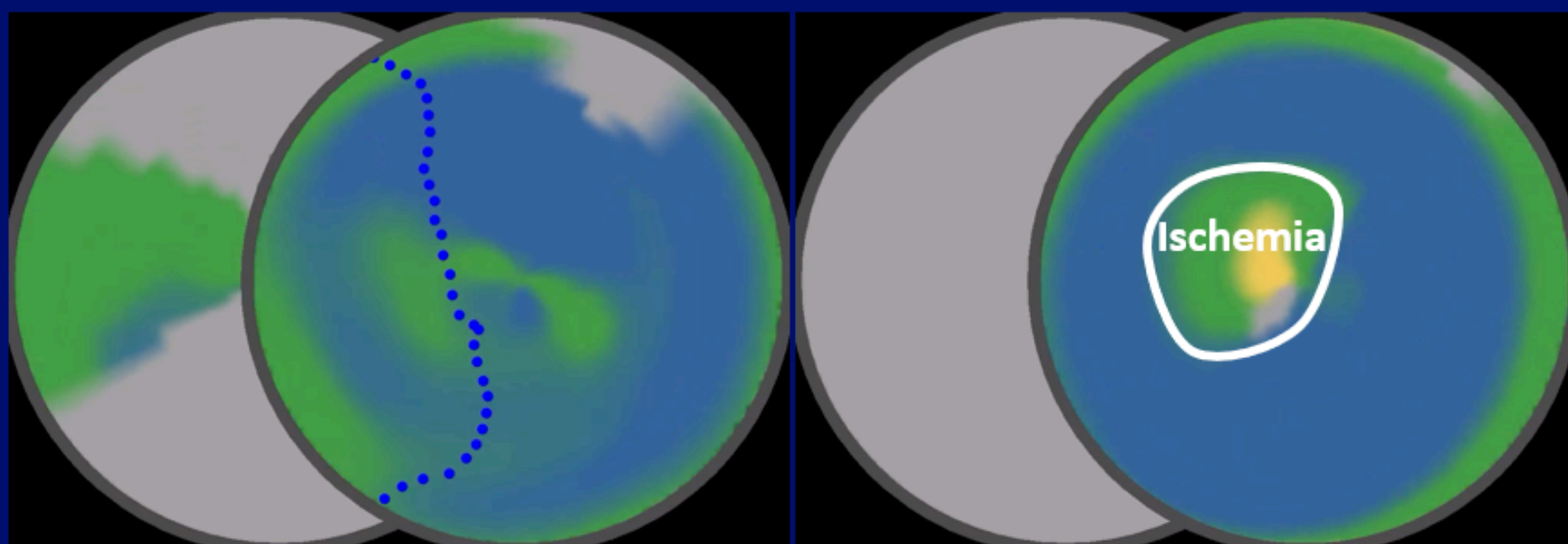
- Cardiac catheterization performed @ day 1
 - Critical stenosis in multiple coronaries
 - 90% LAD / 90% RCA / 50% CX
 - No adverse events through 994 days follow-up

17 | Ischemic Coronary Artery Disease with 90% LAD & 90% RCA Stenoses

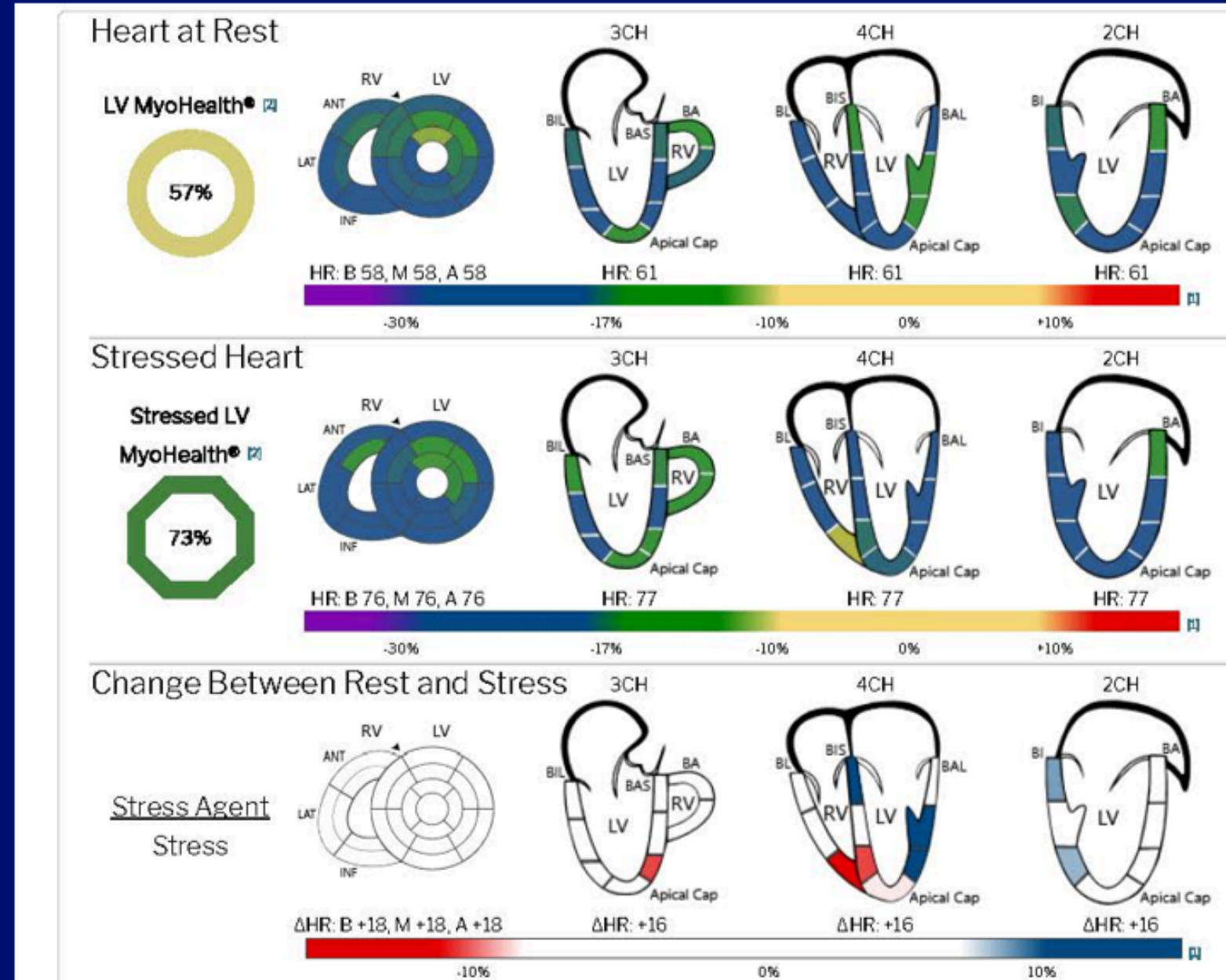
Circumferential

Rest

Stress



17 | Ischemic Coronary Artery Disease with 90% LAD & 90% RCA Stenoses



At Rest: Global Results

Left Ventricle (LV)				Right Ventricle (RV)			
Global MyoStrain®	Result	Normal [1]		Global MyoStrain®	Result	Normal [1]	
MyoStrain (GLS) LV	-17.9 %	(<-17)		MyoStrain (GLS) RV	-19.5 %	(<-17)	
MyoStrain (GCS) LV	-18.9 %	(<-17)		MyoStrain (GCS) RV	-18.2 %	(<-17)	
LV Traditional Measurements	Result	Index	Normal [3]	RV Traditional Measurements	Result	Index	Normal [3]
LVEF	56.4 %	-	(53-74)	RVEF	--	%	(47-69)
LV Mass	115 g	59.59	(39-75) g/m2	RVED Volume	--	ml	(57-108) ml/m2
LVED Volume	144.4 ml	74.84	(53-99) ml/m2	RVES Volume	--	ml	(20-49) ml/m2
LVES Volume	63 ml	32.63	(15-40) ml/m2	RV Stroke Volume	--	ml	(33-62) ml/m2
LV Stroke Volume	81.5 ml	42.22	(35-63) ml/m2				



REPORT

18 | Improvement in Function Post-PCI Despite Ischemia in Residual 90% Diagonal Stenosis

Patient history

- 52-year Male
- Body Mass Index – 29 kg/m²
- Non-Smoker
- Hypercholesterolemia
- Moderate Mitral & Tricuspid Regurgitation
- Known CAD (Prior PCI / DES of LAD; Known 60% stenosis of RCA)

Clinical findings

Baseline CMR Exam – day 0

- NYHA I-II
- LVEF – 50% RVEF – 50%
- MAPSE – 10 mm TAPSE – 20 mm
- Infarct-Typical LGE BIL (< 25%)
- Perfusion Defect < 50% BAS, BIS, BI, MAS, MIS, MI, AS

PCI/DES of RCA – day 7

- RCA stenosis progressed from 60% to 90%, PCI / DES
- No instent restenosis in LAD but 50% stenosis in proximal third, No Intervention

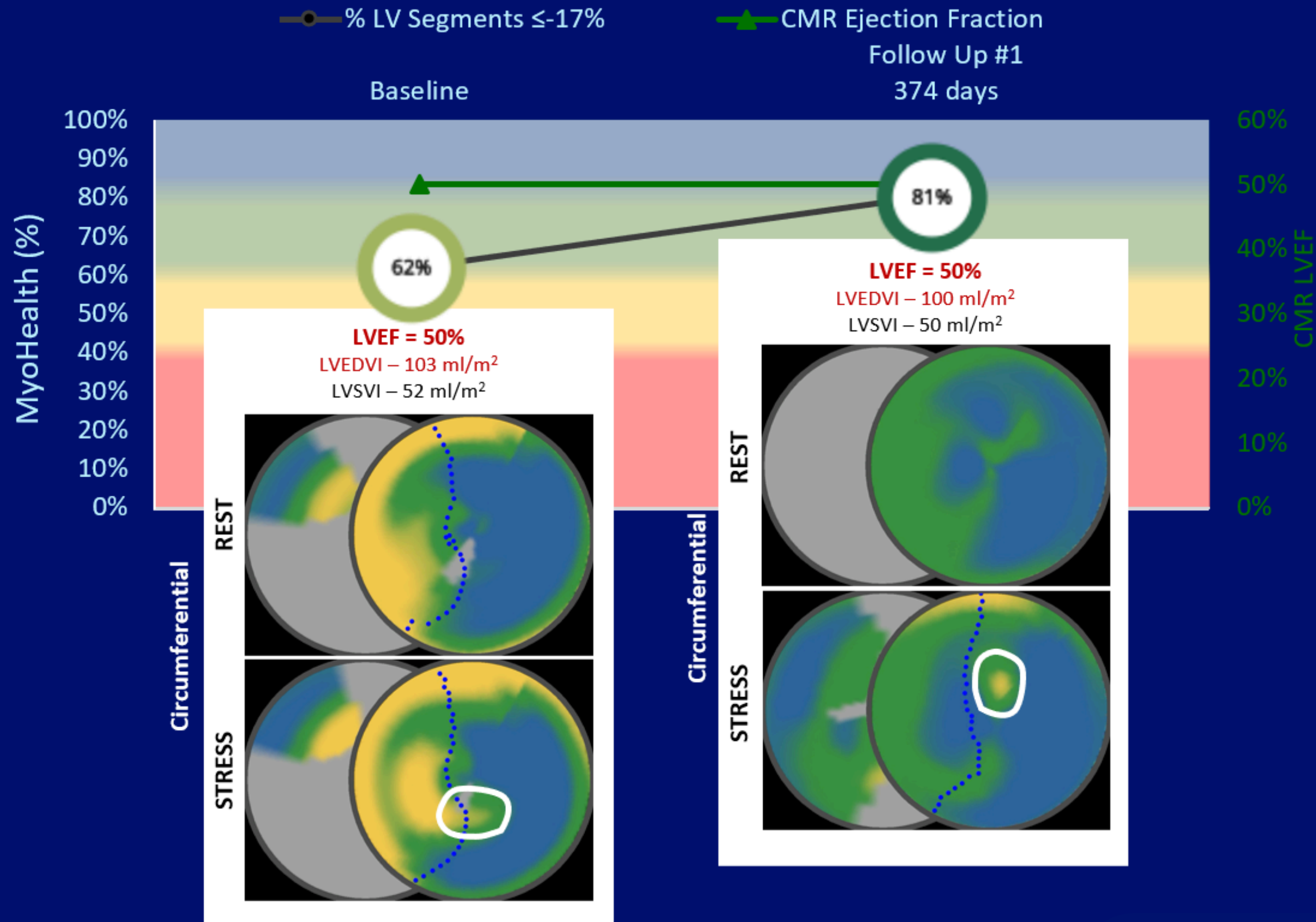
Follow-Up CMR #1 – day 374

- NYHA I-II
- Improved Resting MyoStrain
- LVEF – 50% RVEF – 52%
- MAPSE – 12 mm TAPSE – 30 mm
- Infarct-Typical LGE BIL (< 25%)
- Perfusion Defect < 50% BAS, BIS, MAS, MIS, AS

PCI/DES in Diagonal 1 of LAD – day 402

- RCA good result from prior stented region
- RCX had 30% stenosis proximal, No Intervention
- RIVA of LAD had proximal plaque with 30% stenosis, No Intervention
- D1 of LAD had 90% stenosis (FFR = 0.69) with PCI / DES (FFR = 0.86 after)

18 | Improvement in Function Post-PCI Despite Ischemia in Residual 90% Diagonal Stenosis



19 | MyoStress Indicating Ischemic CAD Consistent with Catheterization

Patient history

- 54 year male, non-smoker
- BMI: 24 kg/m²; BSA: 1.99 m²
- No LV Hypertrophy
 - Septal WT – 9 mm; Lateral WT – 6 mm
- Hypercholesterolemia

Clinical findings

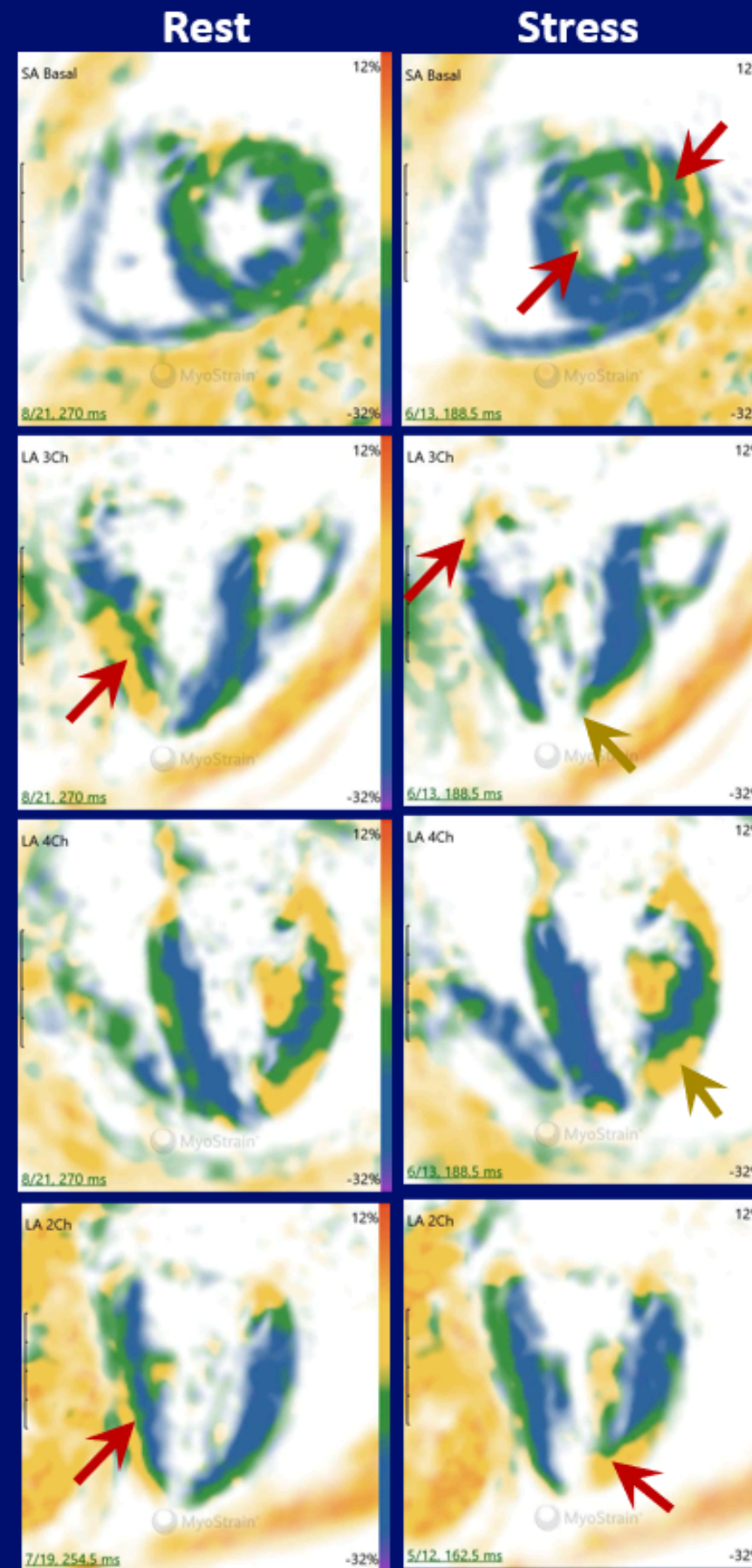
Perfusion CMR with MyoStress (Adenosine)

- NYHA I
- MyoHealth – 60%
 - LVGLS –16.0; LVGCS -17.6
 - 3 ischemic segments (rest – stress \leq -6.5)
 - Slight dyssynchrony observed that worsened during stress
 - Inferior and lateral walls
- LVEF – 55%; Mass Index – 49 g/m²
 - LVEDVI – 76 ml/m²; LVESVI – 34 ml/m²; LVSVI – 42 ml/m²
 - MAPSE – 14 mm
- RVEF – 52%;
 - RVEDVI – 80 ml/m²; RVESVI – 39 ml/m²; RVSVI – 41 ml/m²
 - TAPSE – 24 mm
- LGE score (aLGE x tLGE x Septal WT) – 0.90
- No infarct-typical LGE: tLGE score – 1.00
- No infarct-atypical LGE: aLGE score – 1.00
- No perfusion defects – 1.00

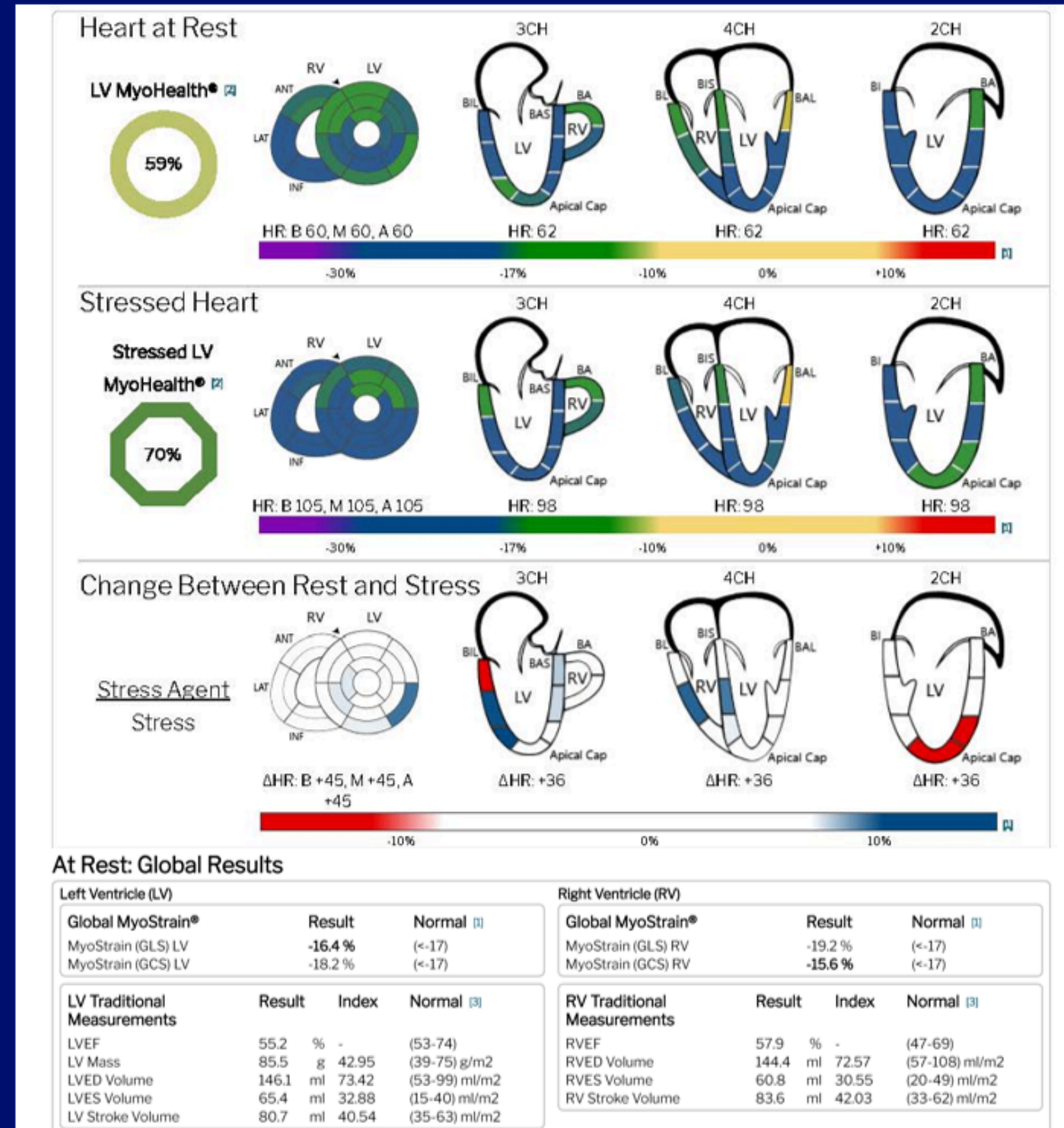
Post-Imaging Follow-Up

- Cardiac catheterization performed after Perfusion CMR stress test
 - Stenosis in multiple coronary territories without intervention
 - 50% LAD / 60% RCA / 50% CX

19 | MyoStress Indicating Ischemic CAD Consistent with Catheterization



19 | MyoStress Indicating Ischemic CAD Consistent with Catheterization



REPORT